

Leukaemia Section

Review

Systemic EBV-positive T-cell lymphoma of childhood

Ashley M. Eckel, Karen M. Chisholm

Department of Laboratory Medicine, University of Washington, Seattle, WA, USA; aeckel@uw.edu (AME); Department of Laboratories, Seattle Children's Hospital, Seattle, WA, USA; karen.chisholm@seattlechildrens.org (KMC)

Published in Atlas Database: October 2019

Online updated version : <http://AtlasGeneticsOncology.org/Anomalies/EBVT-LymphomaChildID1763.html>

Printable original version : <http://documents.irevues.inist.fr/bitstream/handle/2042/70777/10-2019-EBVT-LymphomaChildID1763.pdf>
DOI: 10.4267/2042/70777

This work is licensed under a Creative Commons Attribution-Noncommercial-No Derivative Works 2.0 France Licence.
© 2020 Atlas of Genetics and Cytogenetics in Oncology and Haematology

Abstract

Review on systemic EBV positive T-cell lymphoma of childhood, with data on clinical findings, pathology and genetic alterations.

Keywords

childhood, EBV, hemophagocytosis, lymphoproliferative, lymphoma, T-cell,

Other names

Systemic EBV-positive T-cell lymphoma of childhood has also been termed fulminant EBV-positive T-cell lymphoproliferative disorder of childhood, sporadic fatal infectious mononucleosis, fulminant hemophagocytic syndrome in children, and fatal EBV-associated hemophagocytic syndrome. Use of the term 'severe chronic active EBV (severe CAEBV)' is discouraged for this entity.

Clinics and pathology

Disease

Systemic EBV-positive T-cell lymphoma of childhood is a rapidly progressive, fatal disease of children and young adults characterized by monoclonal expansion of EBV-positive T cells with an activated cytotoxic phenotype in tissues or peripheral blood.

It has a fulminant clinical course typically associated with hemophagocytic syndrome. The prognosis is generally poor, and there is no standard treatment, although therapy may include allogeneic hematopoietic stem cell transplantation.

Note

While this review focuses on systemic EBV-positive T-cell lymphoma of childhood, EBV infection is associated with multiple other non-malignant and malignant disorders. For this particular diagnosis, it is important to distinguish this type of lymphoma from acute self-limited infectious mononucleosis with EBV-infected B cells, and the other EBV-positive lymphoproliferative disorders (LPD) which include aggressive NK-cell leukemia, extranodal NK/T-cell lymphoma, nasal type, and chronic active EBV infection (CAEBV) of T- and NK-cell type (cutaneous and systemic forms). It is frequently particularly challenging to differentiate systemic EBV-positive T-cell lymphoma of childhood from acute EBV-associated hemophagocytic lymphohistiocytosis (EBV-HLH), and the differentiation is often not ultimately made in many cases (Coffey et al. 2019; Smith et al. 2014). It is also important to distinguish this entity from chronic active EBV infection of T- and NK-cell type, which can show a broad range of clinical manifestations, from indolent, localized forms such as hydroa vacciniforme-like lymphoproliferative disorder and severe mosquito bite allergy to more systemic disease manifestations characterized by symptoms similar to systemic EBV-positive T-cell lymphoma of childhood. Correlation of morphological, immunophenotype and clinical features is critical for accurate diagnosis in these cases and these disorders may be a biologic continuum, rather than discrete entities.

Phenotype/cell stem origin

The cell of origin is thought to be transformed, activated cytotoxic T cells.

Etiology

Epstein-Barr virus (EBV) is a herpesvirus with a double-stranded DNA genome. EBV was first discovered from cells isolated from African patients with Burkitt's lymphoma and was later recognized to be highly prevalent worldwide (Epstein et al. 1964), causing chronic latent infection with lifelong persistence in more than 90% of the world's population. EBV has been linked to several malignancies, including nasopharyngeal carcinoma, gastric carcinoma and lymphomas/lymphoproliferative diseases including Burkitt lymphoma, classical Hodgkin lymphoma, post-transplantation lymphoproliferative disorders, NK/T cell lymphoma (nasal type), aggressive NK-cell leukemia, angioimmunoblastic T cell lymphoma. It is thought that these disorders arise due to impaired balance between the host immune response and EBV virus. Given the racial predispositions to some of these disorders, including systemic EBV-positive T-cell lymphoma of childhood, it is postulated that there may be genetic defects in host immune responses to EBV that increase susceptibility to transformation. Additionally, there are genetically different strains of EBV, which may have different propensities for contributing to cancer development (Rickinson et al. 1987; Yakovleva et al. 2015).

Epidemiology

Systemic EBV-positive T-cell lymphoma of childhood is extremely rare but reports of this disease have most frequently been in Asians including individuals from Japan and China (Kikuta et al. 1993; Su et al. 1994; Suzuki et al. 2004; Yoshii et al. 2012; Zhu et al. 2019). Additional reports have described the disorder in several individuals from Mexico, Central and South America, and occasional individuals whose ethnic origin is described as White, not further specified (Coffey et al. 2019; Quintanilla-Martinez et al. 2000). It occurs most often in children and young adults.

Clinics

The disease usually occurs in previously healthy children or adolescents shortly after acute primary EBV infection; however, it has also been described as an evolution from chronic active EBV infection. While reports of the disease are rare, accumulated data from several individual patients suggests that the disease generally develops within days to weeks of infectious mononucleosis symptoms. Patients progress to increasing malaise, high fever,

hepatosplenomegaly, and jaundice with or without minimal lymphadenopathy.

High EBV viral loads, and elevated liver enzymes are common. In serological tests for EBV, IgM antibodies against the viral capsid antigen (VCA) are often low to absent in the majority of patients; yet IgG antibodies against VCA are often positive (Kikuta et al., 1993). Pancytopenia and coagulopathies have also been reported in several of the patients. Similarly, fever, hepatosplenomegaly, and frequent lymphadenopathy are also present in reported cases arising from patients with CAEBV. (Coffey et al. 2019; Kikuta et al. 1993; Quintanilla-Martinez et al. 2000; Zhu et al. 2019). Patients in either group generally develop hemophagocytic lymphohistiocytosis, sepsis, and multiorgan dysfunction, which ultimately lead to death usually within days to weeks.

Cytology

The lymphocytes in this disorder are generally described as small and lacking significant atypia (Quintanilla-Martinez et al. 2000). Some cases are reported to show atypical pleomorphic medium to large-sized lymphoid cells (Hong et al. 2013; Yoshii et al. 2012). Findings of cytologic atypia, if present, may be indistinguishable from those of infectious mononucleosis.

Pathology

By morphology, there is an increase in small lymphoid cells and histiocytes, usually accompanied by hemophagocytosis in the liver, spleen, lymph nodes, and bone marrow. Skin and lungs may also be involved.

Bone marrow biopsies tend to show histiocytic hyperplasia, prominent hemophagocytosis, and an interstitial lymphocytic infiltrate (Figure 1). (Coffey et al. 2019; Quintanilla-Martinez et al. 2000).

Multiple reports describe lymph nodes as being largely unremarkable with preserved architecture and open sinuses, although occasional cases have been described to have partial or more complete destruction with paracortical expansion by a prominent infiltration of small to medium-size atypical lymphocytes and areas of necrosis (Coffey et al. 2019; Hong et al. 2013; Quintanilla-Martinez et al. 2000; Zhu et al. 2019). Variable sinus histiocytosis with erythrophagocytosis has been described.

The liver in reported cases demonstrates infiltration of small lymphocytes in portal, lobular, and sinusoidal areas.

Cholestasis, steatosis, hepatocyte necrosis, and hemophagocytosis can also be seen (Figure 2) (Coffey et al. 2019; Quintanilla-Martinez et al. 2000, Yoshii et al. 2012).

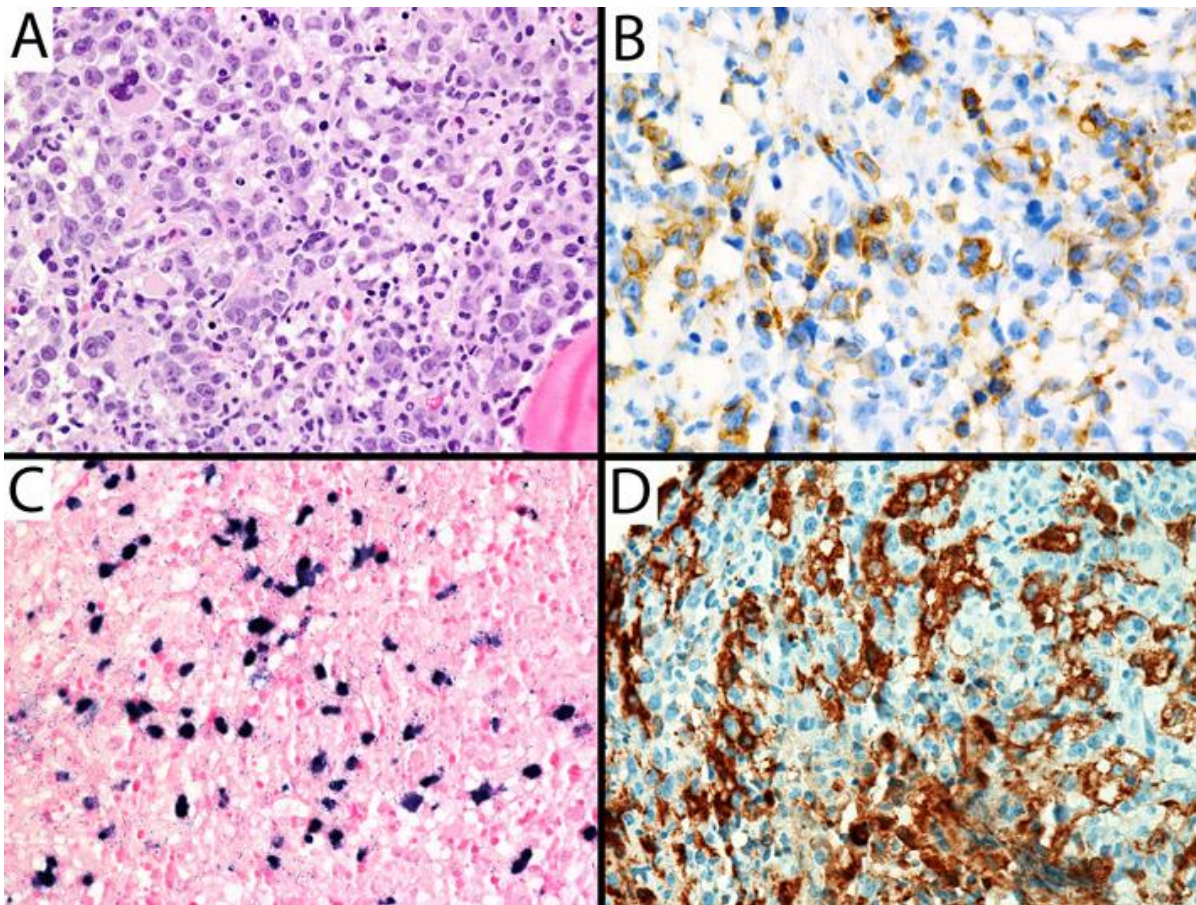


Figure 1: Bone marrow biopsy from a patient diagnosed with systemic EBV-positive T-cell lymphoma of childhood. (A) Numerous scattered intermediate and large sized atypical lymphoid cells and histiocytes with decreased background hematopoiesis. The atypical lymphoid cells are positive for (B) CD8 and (C) EBER. (D) CD163 highlights numerous macrophages, some with hemophagocytosis.

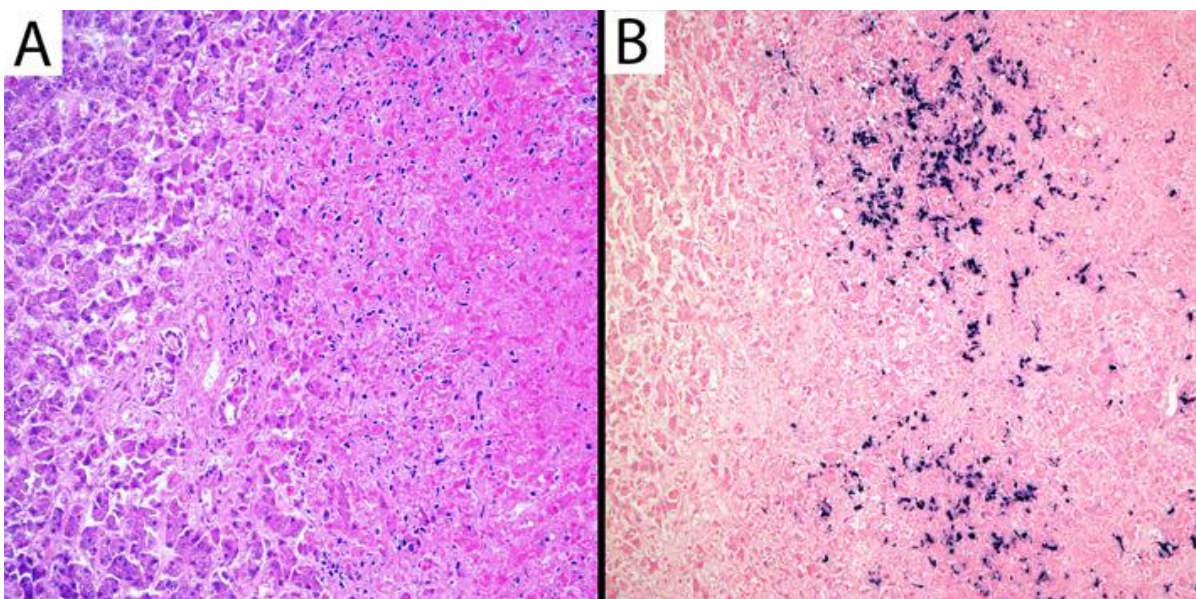


Figure 2: At autopsy, the liver of this 3 year old with systemic EBV positive T-cell lymphoma demonstrated (A) multiple mass forming vasculocentric foci of necrosis (right in photomicrograph) with interspersed atypical lymphocytes at the junction of viable and necrotic liver. (B) These atypical lymphocytes expressed EBV by EBER in situ hybridization.

The spleen can show inconspicuous to markedly depleted white pulp, with a prominent lymphoid infiltration and hemophagocytosis in the splenic sinusoids and occasionally necrosis (Quintanilla-Martinez et al. 2000).

Cytogenetics

No consistent chromosomal aberrations have been identified, although cases with chromosomal aberrations are generally fatal (Smith et al. 2014). The finding of chromosomal aberrations has been suggested as a feature to support a diagnosis of systemic EBV-positive T-cell lymphoma of childhood over EBV-HLH (Kim et al. 2019).

Genes

The infiltrating T lymphocytes show monoclonal rearrangements of the TCR genes, although notably this can also be seen in about half of EBV-HLH cases (Coffey et al. 2019; Kim et al. 2019; Yoshii et al. 2012). All cases of systemic EBV-positive T-cell lymphoma of childhood harbour EBV in a clonal, episomal form (Jones et al. 1988; Kikuta et al. 1993; Suzuki et al. 2004).

Treatment

At present, there is no effective, standard treatment. CHOP-like regimens or immunosuppressive therapies are options, but most patients experience recurrence. Few cases have been reported to respond to an etoposide- and dexamethasone-based regimen typically used for HLH (Coffey et al. 2019; Smith et al. 2014). Additionally, treatment with SMILE regimen (dexamethasone, methotrexate, ifosfamide, L-asparaginase, and etoposide) has been reported in rare patients (Yoshida et al. 2017). The ultimate goal is to get the patients to allogeneic hematopoietic stem cell transplantation (Coffey et al. 2019).

Evolution

The disease usually occurs shortly after acute primary EBV infection in previously healthy children or adolescents but has also been described evolving from a multi-year long course of chronic active EBV infection.

Prognosis

The prognosis is poor with a generally fulminant clinical course with most patients succumbing to the disease within days to weeks. The disease is usually complicated by hemophagocytic syndrome.

References

Coffey AM, Lewis A, Marcogliese AN, Elghetany MT, Punia JN, Chang CC, Allen CE, McClain KL, Gaikwad AS, El-Mallawany NK, Curry CV. A clinicopathologic study of the spectrum of systemic forms of EBV-associated T-cell lymphoproliferative disorders of childhood: A single tertiary care pediatric institution experience in North America. *Pediatr Blood Cancer*. 2019 Aug;66(8):e27798

EPSTEIN MA, ACHONG BG, BARR YM. VIRUS PARTICLES IN CULTURED LYMPHOBLASTS FROM BURKITT'S LYMPHOMA. *Lancet*. 1964 Mar 28;1(7335):702-3

Hong M, Ko YH, Yoo KH, Koo HH, Kim SJ, Kim WS, Park H. EBV-Positive T/NK-Cell Lymphoproliferative Disease of Childhood. *Korean J Pathol*. 2013 Apr;47(2):137-47

Jones JF, Shurin S, Abramowsky C, Tubbs RR, Sciotto CG, Wahl R, Sands J, Gottman D, Katz BZ, Sklar J. T-cell lymphomas containing Epstein-Barr viral DNA in patients with chronic Epstein-Barr virus infections *N Engl J Med* 1988 Mar 24;318(12):733-41

Kanegane H, Bhatia K, Gutierrez M, Kaneda H, Wada T, Yachie A, Seki H, Arai T, Kagimoto S, Okazaki M, Oh-ishi T, Moghaddam A, Wang F, Tosato G. A syndrome of peripheral blood T-cell infection with Epstein-Barr virus (EBV) followed by EBV-positive T-cell lymphoma *Blood* 1998 Mar 15;91(6):2085-91

Kikuta H, Sakiyama Y, Matsumoto S, Oh-Ishi T, Nakano T, Nagashima T, Oka T, Hironaka T, Hirai K. Fatal Epstein-Barr virus-associated hemophagocytic syndrome *Blood* 1993 Dec 1;82(11):3259-64

Kim WY, Montes-Mojarro IA, Fend F, Quintanilla-Martinez L. Epstein-Barr Virus-Associated T and NK-Cell Lymphoproliferative Diseases *Front Pediatr* 2019 Mar 15;7:71

Kimura H, Ito Y, Kawabe S, Gotoh K, Takahashi Y, Kojima S, Naoe T, Esaki S, Kikuta A, Sawada A, Kawa K, Ohshima K, Nakamura S. EBV-associated T/NK-cell lymphoproliferative diseases in nonimmunocompromised hosts: prospective analysis of 108 cases *Blood* 2012 Jan 19;119(3):673-86

Quintanilla-Martinez L, Kumar S, Fend F, Reyes E, Teruya-Feldstein J, Kingma DW, Sorbara L, Raffeld M, Straus SE, Jaffe ES. Fulminant EBV(+) T-cell lymphoproliferative disorder following acute/chronic EBV infection: a distinct clinicopathologic syndrome *Blood* 2000 Jul 15;96(2):443-51

Rickinson AB, Young LS, Rowe M. Influence of the Epstein-Barr virus nuclear antigen EBNA 2 on the growth phenotype of virus-transformed B cells *J Virol* 1987 May;61(5):1310-7

Smith MC, Cohen DN, Greig B, Yenamandra A, Vnencak-Jones C, Thompson MA, Kim AS. The ambiguous boundary between EBV-related hemophagocytic lymphohistiocytosis and systemic EBV-driven T cell lymphoproliferative disorder *Int J Clin Exp Pathol* 2014 Aug 15;7(9):5738-49

Su IJ, Chen RL, Lin DT, Lin KS, Chen CC. Epstein-Barr virus (EBV) infects T lymphocytes in childhood EBV-associated hemophagocytic syndrome in Taiwan *Am J Pathol* 1994 Jun;144(6):1219-25

Suzuki K, Ohshima K, Karube K, Suzumiya J, Ohga S, Ishihara S, Tamura K, Kikuchi M. Clinicopathological states of Epstein-Barr virus-associated T/NK-cell lymphoproliferative disorders (severe chronic active EBV infection) of children and young adults *Int J Oncol* 2004 May;24(5):1165-74

Yakovleva LS, Senyuta NB, Goncharova EV, Scherback LN, Smirnova RV, Pavlish OA, Gurtsevitch VE. [Epstein-Barr Virus LMP1 oncogene variants in cell lines of different origin] *Mol Biol (Mosk)* 2015 Sep-Oct;49(5):800-10

Yoshida M, Osumi T, Imadome KI, Tomizawa D, Kato M, Miyazawa N, Ito R, Nakazawa A, Matsumoto K. Successful treatment of systemic EBV positive T-cell lymphoma of childhood using the SMILE regimen *Pediatr Hematol Oncol* 2018 Mar;35(2):121-124

Yoshii M, Ishida M, Hodohara K, Okuno H, Nakanishi R, Yoshida T, Okabe H. Systemic Epstein-Barr virus-positive T-cell lymphoproliferative disease of childhood: Report of a case with review of the literature *Oncol Lett* 2012 Sep;4(3):381-384

Zhu YY, Duan YT, Song LL, Tao J, Guan YJ, Liu W, Li YG, Shi LH. [Clinicopathological Analysis of Children's Systemic EBV-Positive T-Cell Lymphoma] *Zhongguo Shi Yan Xue Ye Xue Za Zhi* 2019 Aug;27(4):1131-1137

This article should be referenced as such:

Eckel AM, Chisholm KM. Systemic EBV-positive T-cell lymphoma of childhood. *Atlas Genet Cytogenet Oncol Haematol.* 2020; 24(8):316-319.
