

# Leukaemia Section

## Short Communication

### t(6;8)(p21;q24) MYC/SUPT3H

Muntadhar Al Moosawi, H el ene Bruy ere

Hematopathology, Department of Pathology and Laboratory Medicine, muntadhar.almoosawi@vch.ca (MAM); Vancouver General Hospital Cytogenetics Laboratory, Department of Pathology and Laboratory Medicine, University of British Columbia, Vancouver, BC, Canada, helene.bruyere@vch.ca (HB)

Published in Atlas Database: May 2018

Online updated version : <http://AtlasGeneticsOncology.org/Anomalies/t0608p21q24SUPT3H-MYCID2987.html>

Printable original version : <http://documents.irevues.inist.fr/bitstream/handle/2042/70026/05-2018-t0608p21q24SUPT3H-MYCID2987.pdf>

DOI: 10.4267/2042/70026

This work is licensed under a Creative Commons Attribution-Noncommercial-No Derivative Works 2.0 France Licence.  
  2019 Atlas of Genetics and Cytogenetics in Oncology and Haematology

## Abstract

Review on t(6;8)(p21;q24), with data on clinics, and the genes involved.

### Keywords

Blastic, plasmacytoid, dendritic, cell, neoplasm, t(6;8), chromosome 6, chromosome 8

## Identity

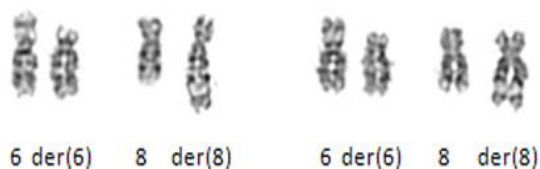

Figure 1: t(6;8)(p21.1;q24.2), G-banding. Courtesy H el ene Bruy ere.

## Clinics and pathology

### Disease

Blastic plasmacytoid dendritic cell neoplasm (BPDCN)

### Phenotype/cell stem origin

Disease derives from precursors of plasmacytoid dendritic cells.

### Epidemiology

The t(6;8) has been found in a limited subset of

BPDCN: Less than 10 cases reported to date. Preponderance of male cases (7/8 to date).

Average age 65 years, in keeping with BPDCN's mean/median age of 61-67 (WHO Classification of Tumours of Hematopoietic and Lymphoid Tissues, 2017).

### Clinics

In general, BPDCN is an aggressive disease that most commonly involves the skin but can also infiltrate the bone marrow and peripheral blood as well as the lymph nodes.

Seven out of eight cases of t(6;8) reported so far had bone marrow involvement based on bone marrow biopsy (Boddu et al., 2018; Momoj et al., 2002; Takiuchi et al., 2012; Nakamura et al., 2015; Fu et al., 2013; personal communication).

One case reported by Leroux et al. in 2002 showed an extensive peripheral blood involvement with 95% circulating blasts.

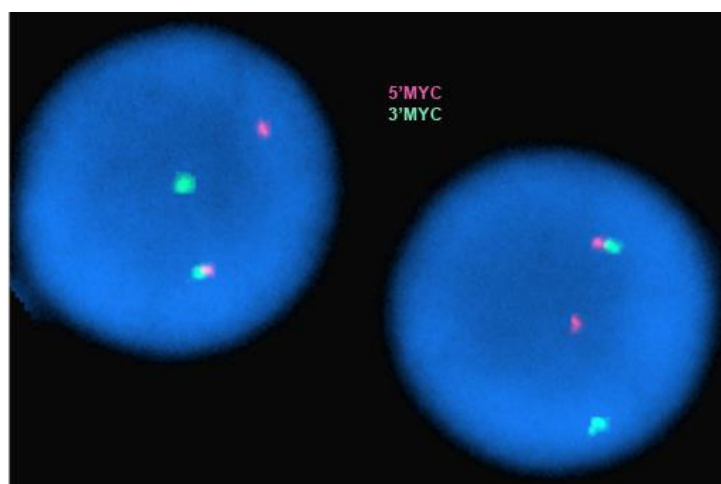
Although a bone marrow biopsy was not performed, the heavy involvement of peripheral blood, indicating bone marrow involvement, was sufficient to make the diagnosis.

### Cytogenetics

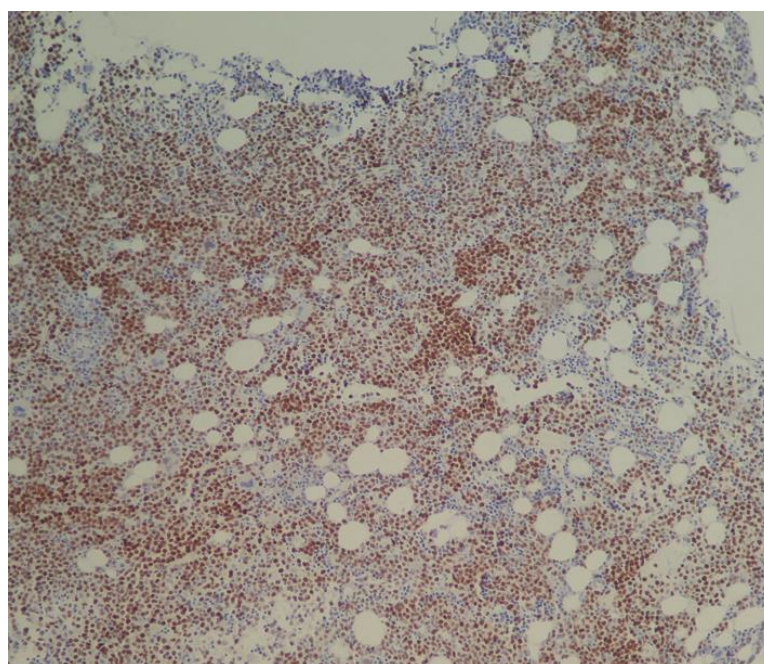
Found with additional abnormalities in all cases, as the sole abnormality in the stemline in one case (Boddu et al., 2018), as a secondary abnormality in one case (Boddu et al., 2018), as part of a complex karyotype in 5/8 cases.

Reference	Age	Sex	Site involved	Karyotype
Momoi et al. 2002	69	M	BM, Skin	46, XY, add(5)(q11), add(5)(q31), t(6;8)(p21,q24), del(13)(q12q14), add(15)(q13)
Boddu et al. 2018	60	M	BM, Skin, LN	46, XY, del(13)(q12q22)[16]/46, idem, t(6;8)(p21;q24.1), del(14)(q24q32)[2]/46, idem, t(6;8)(p21;q24.1), del(14)(q24q32)[cp2]
Boddu et al. 2018	71	M	BM, Skin	46, XY, t(6;8)(p21;q24.2)[5]/47, idem, +18[11]/46, XY[4]
Takiuchi et al. 2012	74	M	BM, spleen	47, XY, t(6;8)(p21;q24), +r
Nakamura et al. 2015	81	M	BM, Skin, LN	47, X, -Y t(6;8)(p21;q24), +add(7)(p11.2), +der(8)t(6;8), +20[17/20], 46, XY[3/20] among LN cells; 48, X, Y, t(6;8)(p21;q24), +add(7)(p11.2), +der(8)t(6;8), +2[5/13], 49, idem, +mar1[2/13], 49, idem, der(8)t(6;8), ?t(9;15)(p22;q15), +mar1 2[13]/46, XY[3/13]
Fu et al. 2013	67	F	BM, LN	46, XX, del(5)(q13q33), t(6;8)(p21;q24)
Leroux et al. 2002	74	M	PB (BM not performed)	49, XY, +add(6)(q21), -8, +2mar, +r[6]/49, idem, t(15;16)(?q21;?q21)[6]/49, idem, t(3;5)(?q21;?q31)[5], ish wcp M-FISH 49, XY, +6, t(6;8)(p21;q24), +r(12), +20/49, idem, inv(15)(q17q273), t(16;16)(q?;q?)/49, idem, t(3;5)(q?21;q?31)[13]
Personal communication	29	M	BM, PB	44-45, X, -Y, del(1)(p12p22), t(6;8)(p21.1;q24.2)[cp5]/46, XY[1], nuc ish(MYCx2)(5'MYC sep 3'MYCx1)[54/100]

**Table 1:** Cases of BPDCN with t(6;8)(q21;q24). BM: bone marrow, LN: lymph node, PB: peripheral blood.



**Figure 2:** FISH image showing the presence of a normal (fused) MYC signal and separated 5'MYC signal from 3'MYC signal.



**Figure 3:** Image from immunohistochemistry with MYC antibody on bone marrow cells.

Of note, cytogenetic abnormalities are present in about two-thirds of BPDCN cases, involving chromosomes 5q34, 12p13, 13q13-21, 15q, and loss of chromosome 9 (WHO Classification of Tumours of hematopoietic and lymphoid tissues, 2017).

### Prognosis

The prognosis of BPDCN is usually poor in adults (Bekkenk et al., 2004, Suzuki et al., 2005) and this appears to be true for cases with t(6;8). Two cases with this translocation failed to respond to treatment, the overall survival being 3 and 12 months respectively (Boddu et al., 2018). One patient relapsed three months after the initial diagnosis and treatment and received multiple lines of chemotherapy but eventually died because of septic shock nine months after the initial diagnosis (Momoi et al., 2002). The only female reported so far with t(6;8) received palliative chemotherapy and died two months after the initial diagnosis. Another patient responded to treatment and tumor cells in the peripheral blood disappeared in day 8; however, the patient died of septic shock on day 16 (Takiuchi et al., 2012). A 29-year-old male patient who was diagnosed with BPDCN with complex karyotype including t(6;8) received ALL-based chemotherapy achieved complete morphological remission by day 24 of treatment and has been on sustained remission at least until this paper was written (personal communication).

### Cytogenetics

The t(6;8)(p21.1;q24.2) is identified by conventional karyotyping.

Note: Other translocations involving 8q24 have been reported in BPDCN: t(8;14)(q24;q32), t(X;8)(q24;q24), t(3;8)(p25;q24) (Boddu et al., 2018; Nakamura et al., 2015)

### Genes involved and proteins

#### MYC

##### Location

14q23.3

##### DNA/RNA

DNA/RNA: CMYC is composed of three exons spanning over 4 kb with the second and third exons encoding most MYC protein.

#### SUPT3H

##### Location

6p21.1

##### DNA/RNA

DNA/RNA: SUPT3H is composed of 22 exons with a size of 570 kb.

#### Protein

399 amino acids and 44 kDa.

### Result of the chromosomal anomaly

#### Hybrid gene

##### Description

The translocation has been shown to result in a split MYC signal when using a commercial MYC break-apart FISH probe (Nakamura et al., 2015, Boddu et al., 2018, Fu et al., 2013). Involvement of the MYC gene has also be inferred from the positive MYC immunohistochemistry observed on bone marrow slides (Nakamura et al., 2015, Boddu et al., 2018). Molecular analysis of the 8q24 breakpoint showed that it occurred in the PVT1 gene on chromosome 8 (Nakamura et al., 2015; Fu et al., 2013; Jardin et al., 2009). PVT1 is located 149 kb telomeric to MYC. It is a long non-coding RNA located within the interval between the 5' MYC probe and 3'MYC commercial probes used to identify MYC rearrangements. Jardin et al. in 2009 found, in BPDCN, a 5.6-Mb interstitial deletion on 8q24 involving PVT1 bringing MYC oncogene adjacent to miR-30b/30c leading to possible up-regulation of these genes.

### References

- Martín-Martín L, López A, Vidriales B, Caballero MD, Rodrigues AS, Ferreira SI, Lima M, Almeida S, Valverde B, Martínez P, Ferrer A, Candeias J, Ruiz-Cabello F, Buadesa JM, Sempere A, Villamor N, Orfao A, Almeida J. Classification and clinical behavior of blastic plasmacytoid dendritic cell neoplasms according to their maturation-associated immunophenotypic profile. *Oncotarget*. 2015 Aug 7;6(22):19204-16
- Momoi A, Toba K, Kawai K, Tsuchiyama J, Suzuki N, Yano T, Uesugi Y, Takahashi M, Aizawa Y. Cutaneous lymphoblastic lymphoma of putative plasmacytoid dendritic cell-precursor origin: two cases. *Leuk Res*. 2002 Jul;26(7):693-8
- Nakamura Y, Kayano H, Kakegawa E, Miyazaki H, Nagai T, Uchida Y, Ito Y, Wakimoto N, Mori S, Bessho M. Identification of SUPT3H as a novel 8q24/MYC partner in blastic plasmacytoid dendritic cell neoplasm with t(6;8)(p21;q24) translocation. *Blood Cancer J*. 2015 Apr 10;5:e301
- Pagano L, Valentini CG, Pulsoni A, Fisogni S, Carluccio P, Mannelli F, Lunghi M, Pica G, Onida F, Cattaneo C, Piccaluga PP, Di Bona E, Todisco E, Musto P, Spadea A, D'Arco A, Pileri S, Leone G, Amadori S, Facchetti F; GIMEMA-ALWP (Gruppo Italiano Malattie EMatologiche dell'Adulto, Acute Leukemia Working Party).. Blastic plasmacytoid dendritic cell neoplasm with leukemic presentation: an Italian multicenter study. *Haematologica*. 2013 Feb;98(2):239-46
- Suzuki R, Nakamura S, Suzumiya J, Ichimura K, Ichikawa M, Ogata K, Kura Y, Aikawa K, Teshima H, Sako M, Kojima H, Nishio M, Yoshino T, Sugimori H, Kawa K, Oshimi K; NK-cell Tumor Study Group.. Blastic natural killer cell lymphoma/leukemia (CD56-positive blastic tumor):

prognostication and categorization according to anatomic sites of involvement. *Cancer*. 2005 Sep 1;104(5):1022-31.

Takiuchi Y, Maruoka H, Aoki K, et al.. Leukemic manifestation of blastic plasmacytoid dendritic cell neoplasm lacking skin lesion: a borderline case between acute monocytic leukemia *J. Clin. Exp. Hematopathol*. 2012 52(2):107-111.

Wiesner T, Obenauf AC, Cota C, Fried I, Speicher MR, Cerroni L.. Alterations of the cell-cycle inhibitors p27(KIP1)

and p16(INK4a) are frequent in blastic plasmacytoid dendritic cell neoplasms. *J Invest Dermatol*. 2010 Apr;130(4):1152-7

---

*This article should be referenced as such:*

Al Moosawi M, Bruyère H. t(6;8)(p21;q24) MYC/SUPT3H. *Atlas Genet Cytogenet Oncol Haematol*. 2019; 23(3):68-71.

---