

Solid Tumour Section

Short Communication

Chromophobe renal cell carcinoma

Paola Dal Cin, Michelle S. Hirsch

Department of Pathology, Brigham, Women's Hospital, 75 Francis Street, Boston, MA 02115, USA

Published in Atlas Database: November 2016

Online updated version : <http://AtlasGeneticsOncology.org/Tumors/ChromophobeRenalID5124.html>

Printable original version : <http://documents.irevues.inist.fr/bitstream/handle/2042/69013/11-2016-ChromophobeRenalID5124.pdf>

DOI: 10.4267/2042/69013

This article is an update of:

Dal Cin P. Kidney: Chromophobe renal cell carcinoma. *Atlas Genet Cytogenet Oncol Haematol* 2002;6(1)

This work is licensed under a Creative Commons Attribution-Noncommercial-No Derivative Works 2.0 France Licence.

© 2017 *Atlas of Genetics and Cytogenetics in Oncology and Haematology*

Abstract

Review on chromophobe renal cell carcinoma, with data on clinics and cytogenetics.

Classification

Chromophobe renal cell carcinoma (ChRCC) is a distinct subtype of renal cell carcinoma, possibly originating from the the distal nephron.

Clinics and pathology

Epidemiology

ChRCC comprise ~5% of all renal cell carcinomas. Most tumors are sporadic, with a slight male predilection.

Pathology

ChRCC tumors can vary in size and have a tan to brown cut surface. The growth pattern is often solid with sheets of cells divided by vascular septae, some of which may have perivascular hyalinized stroma. ChRCC tumor cells have pale cytoplasm and distinct cell membranes. Small eosinophilic cells with granular appearance may be present. Nuclei may appear atypical, but are usually small with wrinkled nuclear membranes and multinucleation (Fig1A). ChRCC grading is complicated by the nuclear atypia, and Fuhrman nuclear grading should not be used. Prognosis is generally favorable with low grade, low stage tumors; but increased cytologic atypia, increased mitotic activity, necrosis, and vascular invasion are poor prognostic indicators. Sarcomatoid

differentiation and high tumor stage are also predictors of poor outcome.

Special stains and immunohistochemistry can be used to distinguish ChRCC from other renal epithelial neoplasms. The presence of Hale's colloidal iron in the cytoplasm of tumor cells is supportive of ChRCC (an apical staining pattern is more supportive of oncocytoma) (Fig.1B). Immunohistochemical expression of CK7 (patchy to diffuse) combined with the absence of S100A1, HNF1beta (nuclear), and CD10 is consistent with a ChRCC.

Occasionally composite oncocytic tumors with features of both oncocytoma and ChRCC tumors have been described, and are most commonly seen in patients with Birt-Hogg-Dube' syndrome and/or oncocytosis.

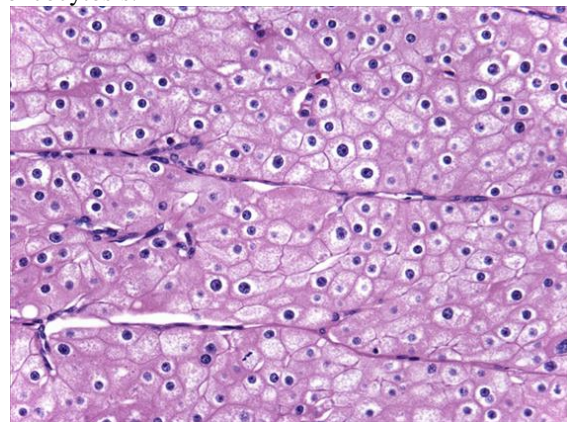


Fig. 1A: ChRCC (H&E stain) is comprised of sheets of tumor cells with well-defined cell borders, round to raisinoid nuclei, and perinuclear halos. Long linear, parallel vessels are common in ChRCC.

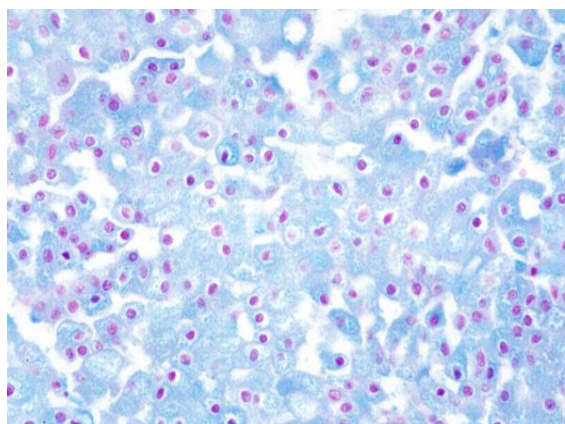


Fig 1B: A Hale's colloidal iron stain is positive (blue) in the cytoplasm of ChRCC tumor cells.

Cytogenetics

Cytogenetics Morphological

Chromophobe RCCs generally have a tendency to grow very slowly in vitro in comparison to all other type of renal tumors. This may be a reason why cytogenetic reports are scarce and usually few metaphases of poor quality were available for investigation. A low chromosome number ranging between 32-39, without discernible structural changes was the most frequent cytogenetic finding. Chromosomes 1, 2, 6, 10, 13, 17 and 21 were most frequently lost (Fig.2). Endoreduplication of the cells with hypodiploid karyotype has been observed. It is of interest, the presence of an hypodiploid clone can be disclosed by a DNA index of 0.86. The low chromosome number has been confirmed by other techniques such as flow cytometry, comparative genomic hybridization (CGH), restriction fragment length polymorphism (RFLP) analysis, and polymorphic microsatellite markers.

Genes involved and Proteins

Note

High resolution DNA-microarray analysis excluded the occurrence of small specific alteration confirming that this combination of monosomies occurs exclusively in chromophobe subtype of RCC. The most commonly mutated genes in chRCC are TP53 and PTEN, combined with

chromosome 17 and 10 deletions (Haake et al 2016).

Whole genomes sequencing identified a number of genomic rearrangements in the TERT promoter region, these same tumors displayed elevated TERT gene expression, suggesting a functional role for these gene fusions.

TERT (telomerase reverse transcriptase)

Location

5p15.33

Note

Structural rearrangements in the TERT promoter region and TERT upregulation are found in a subset of chromophobe RCCs.

Protein

Telomerase encodes a catalytic subunit of the telomerase enzyme, which functions to maintain telomere ends. Telomerase is upregulated in a variety of tumors and plays a role tumor cell immortalization.

PTEN (Phosphatase and Tensin homolog deleted on chromosome Ten)

Location

10q23.31

Note

PTEN mutations are found in approximately 20% of chromophobe RCCs.

Protein

PTEN mutations frequently co-occur with loss of chromosome 10 resulting in complete loss of function. PTEN is a tumor suppressor that functions as a protein and lipid phosphatase and negatively regulates the PI3K-AKT/PKB signaling pathway.

TP53 (Tumour protein p53 (Li-Fraumeni syndrome))

Location

17p13.1

Note

Approximately 32% of chromophobe RCCs have a TP53 mutation.

Protein

TP53 encodes a tumor suppressor protein, which plays a regulatory role in many cellular processes including DNA repair, growth arrest, apoptosis, senescence and metabolism. Mutations in TP53 are found in a broad range of tumor types.

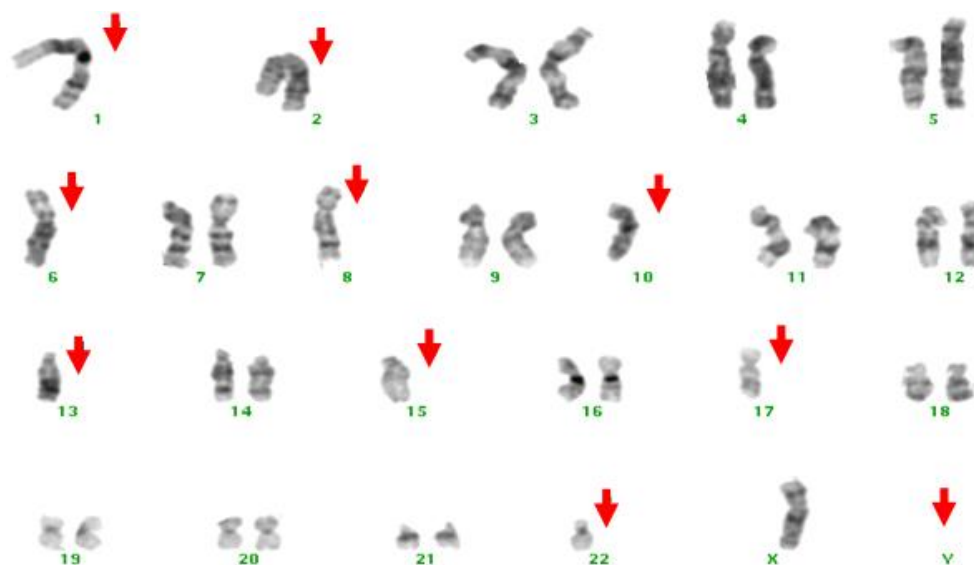


Fig.2. GTG-banded karyotype showing combination of monosomies 1, 2, 6, 8, 10, 13, 15, 17 and 22, and loss of the Y-chromosome

References

Eble J, Delahunt B, Moch H, Martignoni G, Amin MB, Srigley JR, Argani P, Tan PH, Cheville J, Tickoo SK. Papillary adenoma. In: World Health Organization Classification of Tumours: Pathology and Genetics of Tumours of the Urinary System and Male Genital Organs. Moch, H., Humphrey, P.A., Ulbright, T.M., Reuter, V.E. eds; IARC Press, Lyon 2016, 42-43.

Moch, H., Humphrey, P.A., Ulbright, T.M., Reuter, V.E. World Health Organization Classification of Tumours of the Urinary Systems and Male Genital Organs eds (4th edition); IARC Press, Lyon 2016; 11-76.

ICGC Breast Cancer Consortium. Alexandrov LB, Nik-Zainal S, Wedge DC, Aparicio SA, Behjati S, Biankin AV, Bignell GR, Bolli N, Borg A, Børresen-Dale AL, Boyault S, Burkhardt B, Butler AP, Caldas C, Davies HR, Desmedt C, Eils R, Eyfjörd JE, Foekens JA, Greaves M, Hosoda F, Hutter B, Illic T, Imbeaud S, Imielinski M, Jäger N, Jones DT, Jones D, Knappskog S, Kool M, Lakhani SR, López-Otín C, Martin S, Munshi NC, Nakamura H, Northcott PA, Pajic M, Papaemmanuil E, Paradiso A, Pearson JV, Puente XS, Raine K, Ramakrishna M, Richardson AL, Richter J, Rosenstiel P, Schlesner M, Schumacher TN, Span PN, Teague JW, Totoki Y, Tutt AN, Valdés-Mas R, van Buuren MM, van 't Veer L, Vincent-Salomon A, Waddell N, Yates LR; Australian Pancreatic Cancer Genome Initiative; ICGC MMML-Seq Consortium ; ICGC PedBrain

Haake SM, Weyandt JD, Rathmell WK. Insights into the Genetic Basis of the Renal Cell Carcinomas from The Cancer Genome Atlas. *Mol Cancer Res* 2016 Jul;14(7):589-98

Hirsch MS, Signoretti S, Dal Cin P. Adult Renal Cell Carcinoma: A Review of Established Entities from Morphology to Molecular Genetics. *Surg Pathol Clin* 2015 Dec;8(4):587-621

Iqbal MA, Akhtar M, Ulmer C, Al-Dayel F, Paterson MC. FISH analysis in chromophobe renal-cell carcinoma. *Diagn*

Cytopathol 2000 Jan;22(1):3-6

Kovacs A, Kovacs G. Low chromosome number in chromophobe renal cell carcinomas. *Genes Chromosomes Cancer* 1992 Apr;4(3):267-8

Kovacs G, Soudah B, Hoene E. Binucleated cells in a human renal cell carcinoma with 34 chromosomes. *Cancer Genet Cytogenet* 1988 Apr;31(2):211-5

Speicher MR, Schoell B, du Manoir S, Schröck E, Ried T, Cremer T, Störkel S, Kovacs A, Kovacs G. Specific loss of chromosomes 1, 2, 6, 10, 13, 17, and 21 in chromophobe renal cell carcinomas revealed by comparative genomic hybridization. *Am J Pathol* 1994 Aug;145(2):356-64

Srigley JR, Delahunt B, Eble JN, Egevad L, Epstein JI, Grignon D, Hes O, Moch H, Montironi R, Tickoo SK, Zhou M, Argani P; ISUP Renal Tumor Panel

The International Society of Urological Pathology (ISUP) Vancouver Classification of Renal Neoplasia *Am J Surg Pathol*

Störkel S, Steart PV, Drenckhahn D, Thoenes W. The human chromophobe cell renal carcinoma: its probable relation to intercalated cells of the collecting duct. *Virchows Arch B Cell Pathol Incl Mol Pathol* 1989;56(4):237-45

Tan PH, Cheng L, Rioux-Leclercq N, Merino MJ, Netto G, Reuter VE, Shen SS, Grignon DJ, Montironi R, Egevad L, Srigley JR, Delahunt B, Moch H; ISUP Renal Tumor Panel. Renal tumors: diagnostic and prognostic biomarkers *Am J Surg Pathol*

Tickoo SK, Amin MB, Zarbo R. Colloidal iron staining in renal epithelial neoplasms, including chromophobe renal cell carcinoma: emphasis on technique and patterns of staining. *Am J Surg Pathol* 1998 Apr;22(4):419-24

This article should be referenced as such:

Dal Cin P, Hirsch MS. Chromophobe renal cell carcinoma. *Atlas Genet Cytogenet Oncol Haematol.* 2017; 21(12):472-474.