

## Case Report Section

Paper co-edited with the European LeukemiaNet

# Unbalanced rearrangement, der(9;18)(p10;q10) in a patient with myeloproliferative neoplasm: Case 0001M

Kavita S Reddy

Kaiser Permanente Southern California, 4580 ElectronicPlace, Los Angeles, CA 90039, USA (KSR)

Published in Atlas Database: March 2011

Online updated version : <http://AtlasGeneticsOncology.org/Reports/der918Case1ReddyID100052.html>

DOI: 10.4267/2042/46061

This work is licensed under a Creative Commons Attribution-Noncommercial-No Derivative Works 2.0 France Licence.

© 2011 Atlas of Genetics and Cytogenetics in Oncology and Haematology

### Clinics

#### Age and sex

71 years old male patient.

#### Previous history

Preleukemia. No previous malignancy. No inborn condition of note.

#### Organomegaly

No hepatomegaly, splenomegaly (Spleen appears enlarged measures 15.8 cm in length), no enlarged lymph nodes, no central nervous system involvement.

### Blood

WBC : 112.7X 10<sup>9</sup>/l

HB : 13.3g/dl

Platelets : 42X 10<sup>9</sup>/l

### Cyto-Pathology Classification

#### Cytology

MPN (near 100% cellular marrow with granulocytic and megakaryocytic hyperplasia consistent with chronic myeloproliferative neoplasm).

**Immunophenotype:** NA

**Rearranged Ig Tcr:** NA

**Diagnosis:** CMPN

### Survival

**Date of diagnosis:** 10-2004

**Treatment:** Could tolerate Interferon or Hydrea and is on regulated dose of Busulfan.

**Complete remission :** None

**Treatment related death :** NA

**Relapse :** no

**Phenotype at relapse:** NA

**Status:** Alive. Last follow up: 12-2010.

**Survival:** 74 months

### Karyotype

**Sample:** 10/2004 BM, 6/2007 PB and 12/2010 BM

**Culture time:** 24 and 72 hours with overnight Colcemid

**Banding:** GTW at 400 bands

#### Results

10/2004 BM 46,XY[20];

6/2007 PB 46,XY[10];

12/2010 BM 46,XY,+9,der(9;18)(p10;q10)

[8]/46,sl,del(13)(q12q14)[cp6]/46,XY[6]

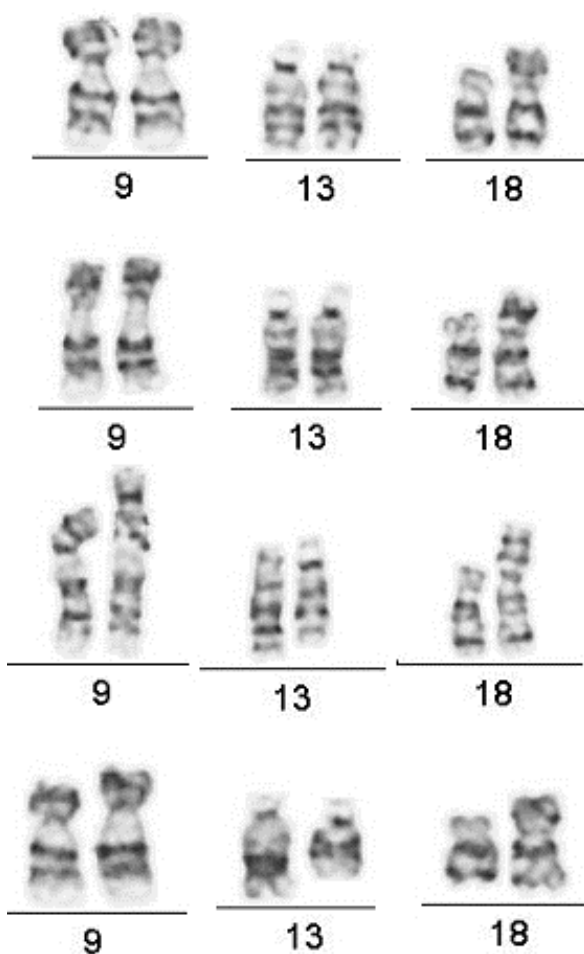
**Karyotype at Relapse:** NA

**Other molecular cytogenetics technics:** None

### Other Molecular Studies

**Technics:** PCR

**Results:** JAK2V617F mutation



Case 0001M : two partial karyotypes of the stemline (row1-2) with 2 normal chromosomes 9 a der(9;18), 13 pairs, a one normal chromosome 18 and arrow). Two partial karyotypes of the sideline (row 3-4) with a normal chromosome 9 pair, a der(9;18), a normal chromosome 13 and a deleted 13 (arrow) and a normal 18 (arrow).

## Comments

Both the cases described in this study were followed for > 5 years. Case 0001M, had thrombocytosis and could not tolerate Interferon or Hydrea treatment and hence was treated with Busulfan. The patient was positive for JAK2 mutation (on chromosome 9). A recent study was to rule out transformation of MPN as there was myelofibrosis, splenomegaly and apparent progression of the disease. The der(9;18) was first identified in the stem line and a sideline had partial deletion of chromosome 13q. Case 0002M was a MDS case with a der(9;18) detected in the initial study and

again when the patient was suspected to be transforming > 5 years later. This patient had very little symptoms and was not treated.

In this report for the first time a long standing MDS case was found to have the der(9;18) at initial diagnosis and after over 5 years. Others reported with der(9;18)(n 7) had PV (n 3) or post PV myelofibrosis (n 4) and one had sAML after ET. The JAK2V617F is a gain in function mutation on chromosome 9. Hence, the extra copy of 9p may exacerbate the MPN as observed in 0001M case. The patient had splenomegaly and also myelofibrosis when the patient was found with the der(9;18). Der(9;18) is the sole abnormality in most reported cases, balanced translocations or complex aberrant karyotypes were reported as additional abnormalities. Our patient had del(13) in a sideline and this abnormality is observed in MPN. Among the 9 patients with der(9;18) two arose post treatment (present case 0001M and Andrieux et al 2003). and the other were at diagnosis.

The der(9;18) supports progression of the disease in case 0001M but in case 0002M with MDS it reappears when there is suspicion of transformation and its role is less uncertain.

## References

- Chen Z, Notohamiprodjo M, Guan XY, Paietta E, Blackwell S, Stout K, Turner A, Richkind K, Trent JM, Lamb A, Sandberg AA. Gain of 9p in the pathogenesis of polycythemia vera. *Genes Chromosomes Cancer*. 1998 Aug;22(4):321-4
- Andrieux J, Demory JL, Caulier MT, Agape P, Wetterwald M, Bauters F, Lai JL. Karyotypic abnormalities in myelofibrosis following polycythemia vera. *Cancer Genet Cytogenet*. 2003 Jan 15;140(2):118-23
- Bacher U, Haferlach T, Schoch C. Gain of 9p due to an unbalanced rearrangement der(9;18): a recurrent clonal abnormality in chronic myeloproliferative disorders. *Cancer Genet Cytogenet*. 2005 Jul 15;160(2):179-83
- Kralovics R, Passamonti F, Buser AS, Teo SS, Tiedt R, Passweg JR, Tichelli A, Cazzola M, Skoda RC. A gain-of-function mutation of JAK2 in myeloproliferative disorders. *N Engl J Med*. 2005 Apr 28;352(17):1779-90
- Xu X, Chen X, Rauch EA, Johnson EB, Thompson KJ, Laffin JJS, Raca G, Kurtycz DF. Unbalanced rearrangement der(9;18)(p10;q10) in a patient with polycythemia vera. *Atlas Genet Cytogenet Oncol Haematol*. April 2010. URL : <http://AtlasGeneticsOncology.org/Reports/der0918XulD100044.html>

*This article should be referenced as such:*

Reddy KS. Unbalanced rearrangement, der(9;18)(p10;q10) in a patient with myeloproliferative neoplasm. Case 0001M. *Atlas Genet Cytogenet Oncol Haematol*. 2011; 15(10):987-988.