

Case Report Section

Paper co-edited with the European LeukemiaNet

Amplification of MLL gene in a new case of acute myeloid leukemia

Sayf Alkatib, Deborah Schloff, Anwar N Mohamed

Cytogenetics Laboratory, Pathology Department, Wayne State University School of Medicine, Detroit Medical Center, Detroit MI, USA (SA, DS, ANM)

Published in Atlas Database: May 2010

Online updated version : <http://AtlasGeneticsOncology.org/Reports/MLLMohamedID100045.html>
DOI: 10.4267/2042/44974

This work is licensed under a Creative Commons Attribution-Noncommercial-No Derivative Works 2.0 France Licence.
© 2011 Atlas of Genetics and Cytogenetics in Oncology and Haematology

Clinics

Age and sex

75 years old female patient.

Previous history

No preleukemia. No previous malignancy. No inborn condition of note.

Organomegaly

No hepatomegaly, no splenomegaly, no enlarged lymph nodes, no central nervous system involvement.

Blood

WBC: 3.00 X 10⁹/l

HB: 9.0g/dl

Platelets: 37.000 X 10⁹/l

Blasts: 18%%

Bone marrow: 90%. Hypercellular (90%) bone marrow with at least 30% blasts. There was dysplasia in all three cell lines.

Cyto-Pathology Classification

Cytology

MDS/AML

Immunophenotype

Flow cytometry identified a population of blasts of myeloid origin encompassing 31% of cells. The blasts were expressing CD13, CD33, CD34, CD117, HLA-DR, and CD56.

Rearranged Ig Tcr

Not performed.

Pathology

Increased and poorly maturing myeloid leukogenesis. Increased erythrocytogenesis with dysplastic forms (nuclear budding and megaloblastoid changes). Megakaryocytogenesis was markedly increased with dysplastic forms (hypolobulated and multiple widely separated nuclei).

Electron microscopy

Not performed.

Diagnosis

Acute myeloid leukemia with multilineage dysplasia.

Survival

Date of diagnosis: 09-2009

Treatment: Gemtuzumab Ozogamicin, and 5-Azacitidine.

Complete remission: None

Status: Dead

Last follow up: 11-2009

Survival: 2 months

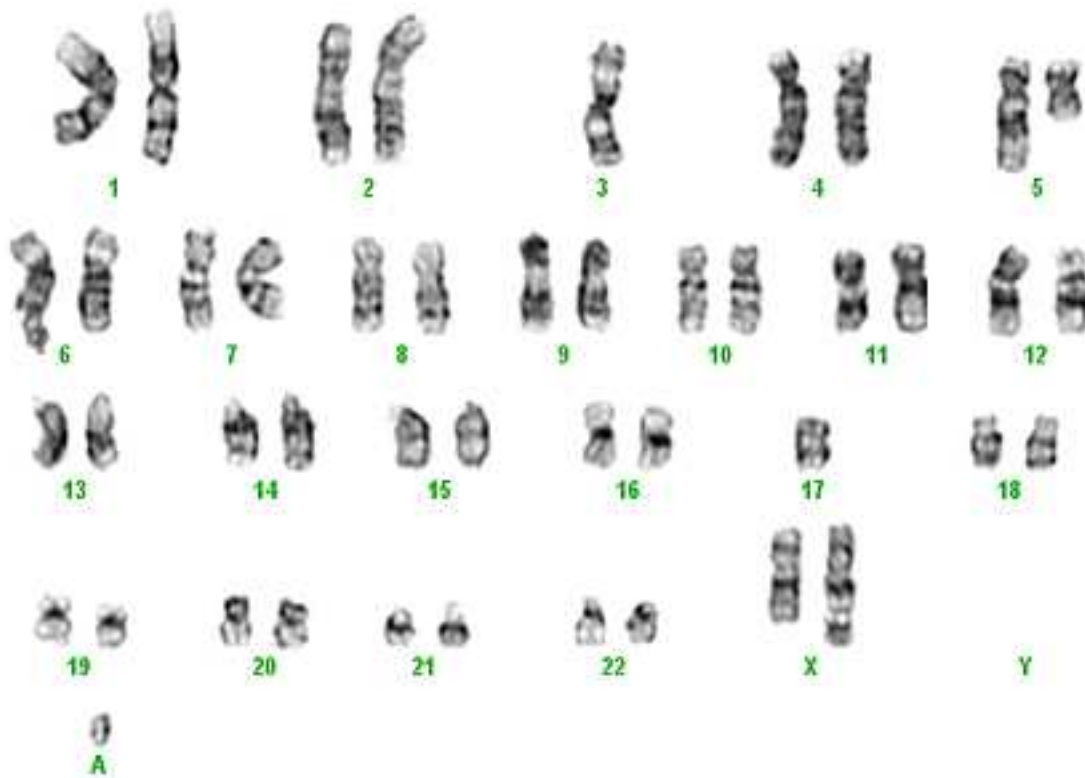
Karyotype

Sample: Bone marrow aspirate.

Culture time: 24h without stimulating agents and 48hr with 10% conditioned medium.

Banding: GTG.

Results: Analysis of 20 metaphase cells revealed an abnormal female karyotype in all metaphases. Very complex chromosomal abnormalities were



G-banded karyotype showing 45,X,add(X)(q22),-3,del(5)(q13q33), hsr(11)(q23),add(12)(p11.2),-17,+r[cp20].

identified. karyotype was designated; 45,X,add(X)(q22),-3,del(5)(q13q33),hsr(11)(q23), add(12)(p11.2),-17,+r[cp20].

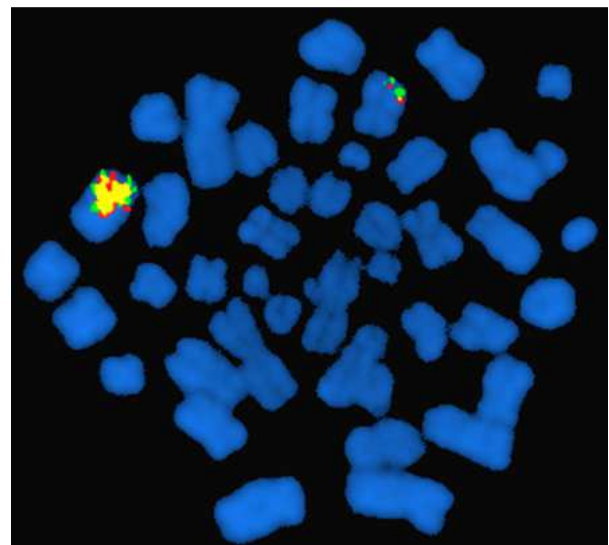
Other Molecular Studies

Technics:

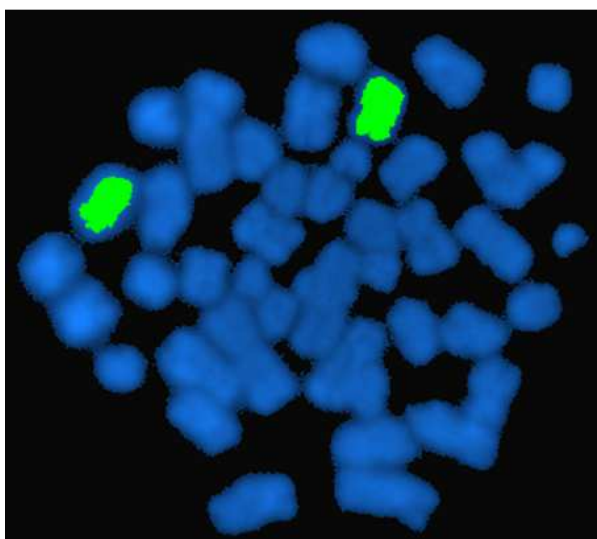
Fluorescence in situ hybridization (FISH) using the LSI EGR1/(5q31)/ D5S23:D5S721 dual color, LSI MLL/11q23 dual color breakapart DNA probes, and whole chromosome paint (WCP) 11 was performed (Vysis Inc. Downers Grove, IL).

Results:

Deletion of EGR1/5q31 was seen in 25% of cells and amplification of MLL/11q23 gene was found in 60% of cells. MLL signals appeared fused indicating lack of MLL rearrangement.



FISH with LSI MLL/11q23 probe showing amplification of MLL gene (arrow) along with one normal copy.



WCP 11 spectrum green on the same metaphase in figure 2 showing two painting signals indicating that the amplified MLL located on chromosome 11 (arrow).

Comments

The case described here is of a 75-year-old female who was diagnosed with AML with multilineage dysplasia. Cytogenetics revealed a complex aberrant karyotype (CAK) including deletion of 5q and loss of chromosome 17. In addition, FISH confirmed deletion of EGR1/5q31 and showed amplification of MLL/11q23 gene in the form of hsr at 11q. Literature suggests an association of amplification of MLL with CAK. Moreover, deletions of 5/5q and 17/17p, such as in our case, are frequently found along with MLL amplification. Previously reported AML cases with MLL amplifications tend to occur in elderly patients, and are characterized by rapid progression, poor response to treatment, and poor clinical outcome. The present case supports the notion that MLL amplification is commonly found in the setting of CAK with deletion of chromosome 5 and 17. Thus, the presence of MLL amplification along with deletion 5q in AML cases appears to be a genomic pattern which signifies a poor prognosis in elderly patients.

References

- Michaux L, Wlodarska I, Stul M, Dierlamm J, Mugneret F, Herens C, Beverloo B, Verhest A, Verellen-Dumoulin C, Verhoef G, Selleslag D, Madoe V, Lecomte M, Deprijck B, Ferrant A, Delannoy A, Marichal S, Duhem C, Dicato M, Hagemeijer A. MLL amplification in myeloid leukemias: A study of 14 cases with multiple copies of 11q23. *Genes Chromosomes Cancer*. 2000 Sep;29(1):40-7
- Dolan M, McGlennen RC, Hirsch B. MLL amplification in myeloid malignancies: clinical, molecular, and cytogenetic findings. *Cancer Genet Cytogenet*. 2002 Apr 15;134(2):93-101
- Poppe B, Vandesompele J, Schoch C, Lindvall C, Mrozek K, Bloomfield CD, Beverloo HB, Michaux L, Dastugue N, Herens C, Yigit N, De Paepe A, Hagemeijer A, Speleman F. Expression analyses identify MLL as a prominent target of 11q23 amplification and support an etiologic role for MLL gain of function in myeloid malignancies. *Blood*. 2004 Jan 1;103(1):229-35
- Zatkova A, Ullmann R, Rouillard JM, Lamb BJ, Kuick R, Hanash SM, Schnittger S, Schoch C, Fonatsch C, Wimmer K. Distinct sequences on 11q13.5 and 11q23-24 are frequently coamplified with MLL in complexly organized 11q amplicons in AML/MDS patients. *Genes Chromosomes Cancer*. 2004 Apr;39(4):263-76
- Papenhausen PR, Griffin S, Tepperberg J. Oncogene amplification in transforming myelodysplasia. *Exp Mol Pathol*. 2005 Oct;79(2):168-75
- Herry A, Douet-Guilbert N, Guéganic N, Morel F, Le Bris MJ, Berthou C, De Braekeleer M. Del(5q) and MLL amplification in homogeneously staining region in acute myeloblastic leukemia: a recurrent cytogenetic association. *Ann Hematol*. 2006 Apr;85(4):244-9
- Pajuelo-Gámez JC, Cervera J, García-Casado Z, Mena-Durán AV, Valencia A, Barragán E, Such E, Bolufer P, Sanz MA. MLL amplification in acute myeloid leukemia. *Cancer Genet Cytogenet*. 2007 Apr 15;174(2):127-31
- Maitta RW, Cannizzaro LA, Ramesh KH. Association of MLL amplification with poor outcome in acute myeloid leukemia. *Cancer Genet Cytogenet*. 2009 Jul;192(1):40-3
- Zatkova A, Merk S, Wendehack M, Bilban M, Muzik EM, Muradyan A, Haferlach C, Haferlach T, Wimmer K, Fonatsch C, Ullmann R. AML/MDS with 11q/MLL amplification show characteristic gene expression signature and interplay of DNA copy number changes. *Genes Chromosomes Cancer*. 2009 Jun;48(6):510-20

This article should be referenced as such:

Alkatib S, Schloff D, Mohamed AN. Amplification of MLL gene in a new case of acute myeloid leukemia. *Atlas Genet Cytogenet Oncol Haematol*. 2011; 15(2):236-238.