

Solid Tumour Section

Mini Review

Soft tissue tumors: Alveolar rhabdomyosarcoma

Frederic G Barr

Department of Pathology and Laboratory Medicine, University of Pennsylvania School of Medicine, Philadelphia, PA 19104, USA (FGB)

Published in Atlas Database: January 2009

Online updated version : <http://AtlasGeneticsOncology.org/Tumors/AlvRhabdomyosarclD5194.html>

DOI: 10.4267/2042/44650

This work is licensed under a Creative Commons Attribution-Noncommercial-No Derivative Works 2.0 France Licence.
© 2009 Atlas of Genetics and Cytogenetics in Oncology and Haematology

Identity

Note: Alveolar rhabdomyosarcoma (ARMS) refers to one subtype of the rhabdomyosarcoma family of soft tissue tumors. These are mesenchymal tumours related to the skeletal muscle lineage.

Classification

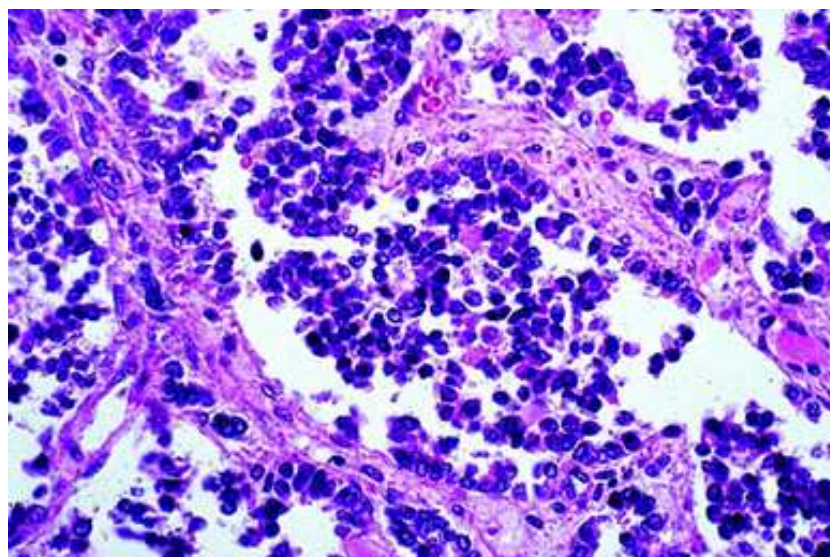
ARMS is one of two subtypes of rhabdomyosarcoma. The other major subtype is embryonal rhabdomyosarcoma (ERMS). Within the ARMS subtype, there is no further histopathologic subtyping of clinical significance. Genetic

subtyping has identified PAX3-FKHR, PAX7-FKHR, and fusion-negative subsets of ARMS; the clinical significance of these subsets is still being actively investigated.

Clinics and pathology

Embryonic origin

ARMS tends to occur within skeletal muscle and is postulated to derive from precursor cells within the skeletal muscle. Therefore, the embryonic derivation of these tumors is presumed to be mesoderm, the same as that of skeletal muscle.



Histopathology of alveolar rhabdomyosarcoma
(hematoxylin-eosin, original magnification: 100X; courtesy of Dr. Linda Ernst).

Epidemiology

ARMS accounts for 20-30% of all RMS tumors. Therefore ARMS represents ~1% of all malignancies among children and adolescents, and has an annual incidence of ~1 per million. Many ARMS tumors occur in older children and young adults - this age association characterizes the more prevalent PAX3-FKHR-positive subset of ARMS. In contrast, PAX7-FKHR-positive ARMS as well as fusion-negative tumors tend to occur in younger children.

Clinics

ARMS often occurs within skeletal muscle of the extremities but can also occur in other sites including the trunk and head and neck. This tumor often presents as a painless mass, but in other cases, may be discovered from symptoms produced by compression of structures at the primary site. A substantial fraction of patients with ARMS (25-30%) will have metastatic disease at the time of diagnosis. ARMS most frequently spreads to bone marrow, distal nodes, and bone. The standard treatment for ARMS is a combination of surgery, radiation, and intensive chemotherapy.

Pathology

Tumor cells in ARMS are relatively small with scant cytoplasm. They have round regular nuclei with a monotonous chromatin pattern. The cells form aggregates interrupted by fibrovascular septae, and within these aggregates, areas of discohesion often form, resulting in spaces that resemble alveoli of the lung. In some ARMS cases, there are few fibrovascular septae, no alveoli-like spaces, and a predominant cellular small round cell population; the term "solid variant" applies to this situation.

In addition to general immunohistochemical markers to identify RMS, certain markers aid in the identification of ARMS. Immunostaining for myogenin and MyoD show different patterns between ARMS and ERMS, such that most cells within an ARMS tumor stain positive whereas fewer cells within an ERMS tumor stain positive. In addition, based on microarray studies that

distinguish fusion-positive ARMS from fusion-negative ERMS, AP2 β and p-cadherin were found to be specific markers for the fusion-positive ARMS subtype.

Prognosis

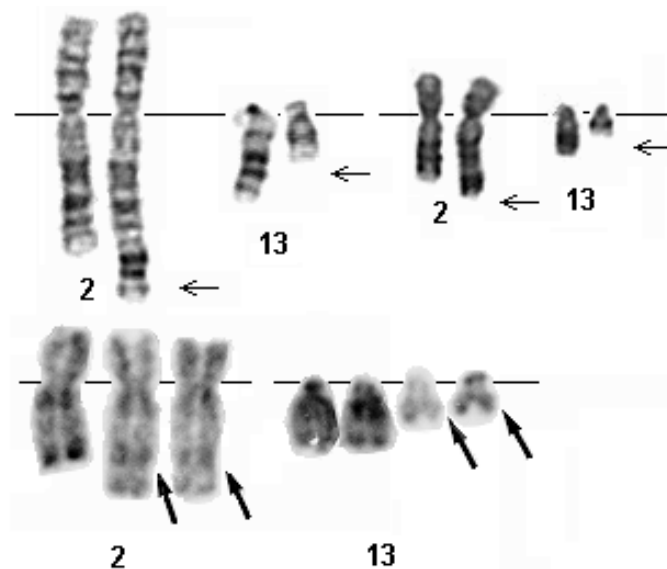
Patients with ARMS tumors have a poorer outcome than patients with ERMS tumors. The 4-year failure free survival rates for patients with localized and metastatic ARMS are 65% and 15%, respectively. Other risk factors that influence outcome of ARMS include primary site, size of primary tumor, extent of local spread, and the presence of nodal and distal metastases.

In an analysis of patients from the IRS-IV study, patients with localized PAX3-FKHR and PAX7-FKHR-positive ARMS had comparable outcomes. In contrast, among patients presenting with metastatic disease, those with PAX3-FKHR-positive tumors had a significantly poorer outcome than those with PAX7-FKHR-positive tumors (4-year overall survival rate of 8% compared to 75%, $p=0.0015$).

Genetics

Note

Most cases of ARMS occur sporadically without an apparent genetic predisposition.



Examples of 2;13 translocation from ARMS tumors. G-banding (above) - Courtesy G. Reza Hafez, Eric B. Johnson, and Sara Morrison-Delap, Cytogenetics at the Waisman Center ; R- banding (below) - Courtesy Jean-Luc Lai.

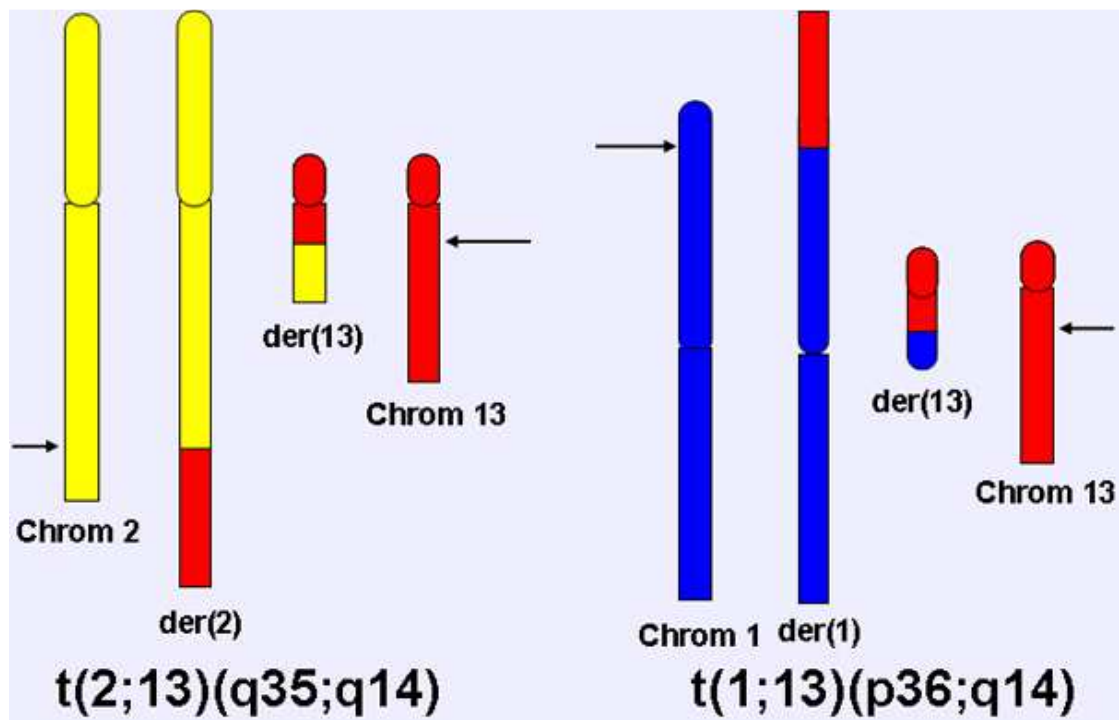


Diagram of $t(2;13)(q35;q14)$ and $t(1;13)(p36;q14)$ chromosomal translocations.

Cytogenetics

Cytogenetics Morphological

Most ARMS cases contain one of two recurrent chromosomal translocations: $t(2;13)(q35;q14)$ or $t(1;13)(p36;q14)$.

Reciprocal balanced translocations are often present for the 2;13 translocation. The 1;13 is sometimes visible as a balanced translocation, and other times is associated with a subsequent amplification event.

Additional cytogenetic changes in ARMS include:

- Amplification events involving 12q13-15, 2p24, 1p36, 13q14, 2q34-qter, 13q31 (as determined by comparative genomic hybridization studies).
- Numerical chromosome gains, such as chromosomes 2, 12, and 20.

Genes involved and proteins

FOXO1

Location

13q14

Protein

Transcription factor.

PAX3

Location

2q35

Protein

Transcription factor.

PAX7

Location

1p36

Protein

Transcription factor.

Result of the chromosomal anomaly

Hybrid Gene

Description

The 2;13 and 1;13 translocations rearrange the PAX3 or PAX7 gene on chromosome 2 or 1 and the FOXO1 gene on chromosome 13 to generate a PAX3-FOXO1 or PAX7-FOXO1 fusion gene.

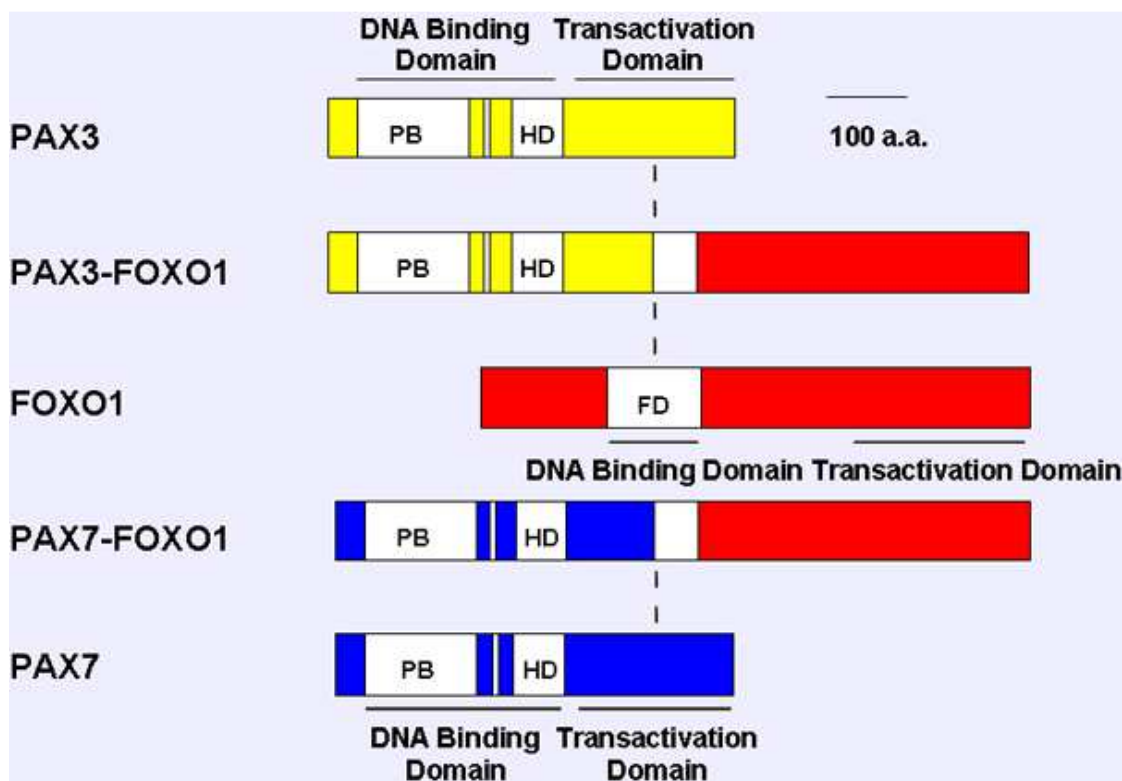
Among ARMS tumors, ~60% are PAX3-FOXO1-positive, ~20% are PAX7-FOXO1-positive, and ~20% are fusion-negative.

The PAX7-FKHR fusion is often amplified in tumors (70% of PAX7-FKHR-positive cases) whereas the PAX3-FKHR gene fusion is much less frequently amplified in tumors (5% of PAX3-FKHR-positive cases). Gene amplification appears to be one mechanism to increase the expression level of the gene fusion in ARMS tumor cells.

Fusion Protein

Description

These fusion genes encode fusion transcription factors with a PAX3 or PAX7 DNA binding domain and FOXO1 transactivation domain.



Comparison of wild-type and fusion products associated with the 2;13 and 1;13 translocations. The paired box, octapeptide, homeobox and fork head domain are indicated as open boxes, and transcriptional domains (DNA binding domain, DBD; transcriptional activation domain) are shown as solid bars. The vertical dash line indicates the translocation fusion point.

Expression / Localisation

Nuclear.

Oncogenesis

Transcription dysregulation.

References

Gurney JG, Young JL, Roffers SD, Smith MA, Bunin GR.. Soft Tissue Sarcomas. In L. A. Ries, M. A. Smith, J. G. Gurney, M. Linet, T. Tamra, J. L. Young, and G. R. Bunin (ed.), Cancer Incidence and Survival among Children and Adolescents: United States SEER Program 1975-1995. NIH Pub. No. 99-4649, Bethesda, MD. 1999; p. 111-124.

Turc-Carel C, Lizard-Nacol S, Justrabo E, Favrot M, Philip T, Tabone E. Consistent chromosomal translocation in alveolar rhabdomyosarcoma. *Cancer Genet Cytogenet.* 1986 Jan 15;19(3-4):361-2

Wang-Wuu S, Soukup S, Ballard E, Gotwals B, Lampkin B. Chromosomal analysis of sixteen human rhabdomyosarcomas. *Cancer Res.* 1988 Feb 15;48(4):983-7

Barr FG, Galili N, Holick J, Biegel JA, Rovera G, Emanuel BS. Rearrangement of the PAX3 paired box gene in the paediatric solid tumour alveolar rhabdomyosarcoma. *Nat Genet.* 1993 Feb;3(2):113-7

Galili N, Davis RJ, Fredericks WJ, Mukhopadhyay S, Rauscher FJ 3rd, Emanuel BS, Rovera G, Barr FG. Fusion of a fork head domain gene to PAX3 in the solid tumour alveolar rhabdomyosarcoma. *Nat Genet.* 1993 Nov;5(3):230-5

Davis RJ, D'Cruz CM, Lovell MA, Biegel JA, Barr FG. Fusion of PAX7 to FKHR by the variant t(1;13)(p36;q14) translocation in alveolar rhabdomyosarcoma. *Cancer Res.* 1994 Jun 1;54(11):2869-72

Barr FG, Nauta LE, Davis RJ, Schäfer BW, Nycum LM,

Biegel JA. In vivo amplification of the PAX3-FKHR and PAX7-FKHR fusion genes in alveolar rhabdomyosarcoma. *Hum Mol Genet.* 1996 Jan;5(1):15-21

Weber-Hall S, Anderson J, McManus A, Abe S, Nojima T, Pinkerton R, Pritchard-Jones K, Shipley J. Gains, losses, and amplification of genomic material in rhabdomyosarcoma analyzed by comparative genomic hybridization. *Cancer Res.* 1996 Jul 15;56(14):3220-4

Davis RJ, Barr FG. Fusion genes resulting from alternative chromosomal translocations are overexpressed by gene-specific mechanisms in alveolar rhabdomyosarcoma. *Proc Natl Acad Sci U S A.* 1997 Jul 22;94(15):8047-51

Kelly KM, Womer RB, Sorensen PH, Xiong QB, Barr FG. Common and variant gene fusions predict distinct clinical phenotypes in rhabdomyosarcoma. *J Clin Oncol.* 1997 May;15(5):1831-6

Gordon AT, Brinkschmidt C, Anderson J, Coleman N, Dockhorn-Dworniczak B, Pritchard-Jones K, Shipley J. A novel and consistent amplicon at 13q31 associated with alveolar rhabdomyosarcoma. *Genes Chromosomes Cancer.* 2000 Jun;28(2):220-6

Barr FG. Gene fusions involving PAX and FOX family members in alveolar rhabdomyosarcoma. *Oncogene.* 2001 Sep 10;20(40):5736-46

Crist WM, Anderson JR, Meza JL, Fryer C, Raney RB, Ruyman FB, Breneman J, Qualman SJ, Wiener E, Wharam M, Lobe T, Webber B, Maurer HM, Donaldson SS. Intergroup rhabdomyosarcoma study-IV: results for patients with nonmetastatic disease. *J Clin Oncol.* 2001 Jun 15;19(12):3091-102

Bridge JA, Liu J, Qualman SJ, Suijkerbuijk R, Wenger G, Zhang J, Wan X, Baker KS, Sorensen P, Barr FG. Genomic gains and losses are similar in genetic and histologic subsets of rhabdomyosarcoma, whereas amplification predominates in embryonal with anaplasia and alveolar subtypes. *Genes Chromosomes Cancer*. 2002 Mar;33(3):310-21

Sorensen PH, Lynch JC, Qualman SJ, Tirabosco R, Lim JF, Maurer HM, Bridge JA, Crist WM, Triche TJ, Barr FG. PAX3-FKHR and PAX7-FKHR gene fusions are prognostic indicators in alveolar rhabdomyosarcoma: a report from the children's oncology group. *J Clin Oncol*. 2002 Jun 1;20(11):2672-9

Breneman JC, Lyden E, Pappo AS, Link MP, Anderson JR, Parham DM, Qualman SJ, Wharam MD, Donaldson SS, Maurer HM, Meyer WH, Baker KS, Paidas CN, Crist WM. Prognostic factors and clinical outcomes in children and adolescents with metastatic rhabdomyosarcoma--a report from the Intergroup Rhabdomyosarcoma Study IV. *J Clin Oncol*. 2003 Jan 1;21(1):78-84

Sebire NJ, Malone M. Myogenin and MyoD1 expression in paediatric rhabdomyosarcomas. *J Clin Pathol*. 2003 Jun;56(6):412-6

Parham DM, Ellison DA. Rhabdomyosarcomas in adults

and children: an update. *Arch Pathol Lab Med*. 2006 Oct;130(10):1454-65

Wachtel M, Runge T, Leuschner I, Stegmaier S, Koscielniak E, Treuner J, Odermatt B, Behnke S, Niggli FK, Schäfer BW. Subtype and prognostic classification of rhabdomyosarcoma by immunohistochemistry. *J Clin Oncol*. 2006 Feb 10;24(5):816-22

Wexler LH, Meyer WH, Helman LJ.. Rhabdomyosarcoma and the undifferentiated sarcomas. In P. A. Pizzo and D. G. Poplack (ed.), *Principles and Practice of Pediatric Oncology*, 2006. Fifth ed. Lippincott Williams & Wilkins, Philadelphia; p. 971-1001.

This article should be referenced as such:

Barr FG. Soft tissue tumors: Alveolar rhabdomyosarcoma. *Atlas Genet Cytogenet Oncol Haematol*. 2009; 13(12):981-985.
