

Case Report Section

Paper co-edited with the European LeukemiaNet

A case of trisomy 8 and loss of the Y-chromosome as secondary aberrations in a ten year old boy with de novo AML FAB M2 and t(16;21)(q24;q22)

Jutta Bradtke, Peter Vorwerk, Jochen Harbott

Fachhumangenetikerin GfH, Oncogenetic Laboratory, Dept. Ped. Hematology / Oncology, Schlangenzahl 14, 35385 Giessen, Germany

Published in Atlas Database: November 2007

Online updated version: <http://AtlasGeneticsOncology.org/Reports/1621BradtkeID100031.html>
DOI: 10.4267/2042/38618

This work is licensed under a Creative Commons Attribution-Non-commercial-No Derivative Works 2.0 France Licence.
© 2008 Atlas of Genetics and Cytogenetics in Oncology and Haematology

Clinics

Age and sex: 10 years old male patient.

Previous History:

- no preleukemia;
- no previous malignant disease;
- no inborn condition of note.

Organomegaly:

- hepatomegaly;
- no splenomegaly;
- no enlarged lymph nodes;
- no central nervous system involvement

Blood

WBC: 34 x 10⁹/l; Hb: 8,2 g/dl; platelets: 57x 10⁹/l;
blasts: 92%

Bone marrow: 94%

Cytopathology classification

Cytology: M2 without Auer rods; Peroxidase (+) esterase (+).

Immunophenotype: CD13+, CD33+

Pathology: -

Electron microscopy: -

Precise diagnosis: ANLL M2

Survival

Date of diagnosis: 06-2007.

Treatment: AML BFM Protocol (high risk).

Complete remission was obtained.

Treatment related death: -

Relapse: -

Status: Alive 09-2007.

Karyotype

Sample: Bone Marrow;

Culture time: two cultures 48 hours;


Banding: GTG-Banding.

Results: 46,X,-Y,+8,t(16;21)(q24;q22)

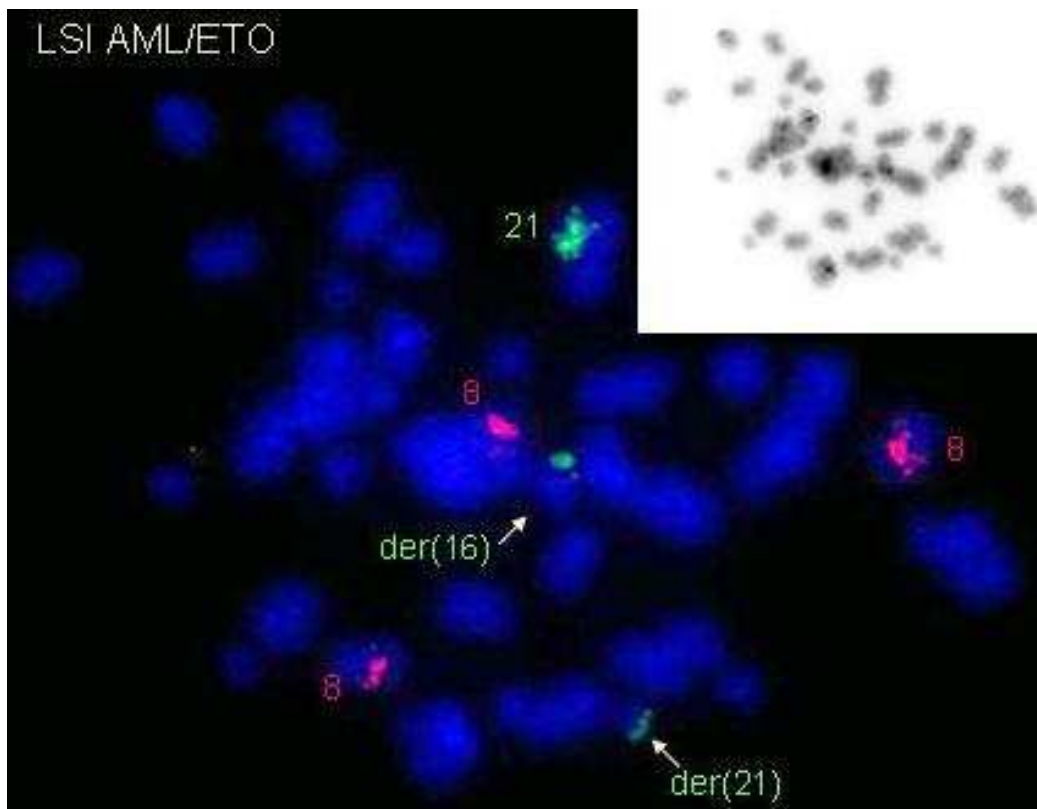
Other molecular studies

Technics: FISH evaluation for AML1 rearrangement and trisomy 8 was performed on abnormal metaphases after 48h of cultivation with the LSI AML1/ETO Dual Color Probe (Abbott Molecular/Vysis, Inc.).

Results: ish +8(ETO x 3), der(16)t(16;21) (dimAML1+), der(21)t(16;21) (dimAML1+)



GTG-banded chromosomes which are representing the trisomy 8 and the t(16;21).



DAPI stained and inverted metaphase which shows three signals for ETO (red) and three signals for AML1 (green, one signal splitted).

Comments

The t(16;21)(q24;q22) is a rare aberration in AML with 16 cases described in the Mitelman-database and it is extreme rare in children (only two cases published). Most of these 16 cases are classified to the FAB M2 subtype and a trisomy 8 was seen as a recurrent secondary aberration of t(16;21). Loss of one sex chromosome as a secondary aberration of t(16;21) has not been described yet. This is to our knowledge the first case of an AML with t(16;21)(q24;q22), trisomy 8 and loss of the Y-chromosome. The specific aberration for AML M2 is the t(8;21)(q22;q22), which shows often a loss of one sex chromosome (seen in 50% of the cases) and in 10% a trisomy 8 as secondary aberrations (Huret, 1997). Maybe the t(16;21)(q24;q21) is a rare equivalent of the t(8;21), because 1) the same gene RUNX1, located on (21)(q22), is involved and has similar genes as translocation partners: RUNX1T1 (ETO) in the t(8;21) and CBFA2T3 in the t(16;21); both are coding for ETO proteins, 2) the t(16;21) occurs often in cases with the same AML M2 morphology, and 3) patients with t(16;21) show the same additional chromosome anomalies (-Y/+8). While trisomy 8 is quite frequent in various leukemias the loss of the Y chromosome is a very specific secondary aberration of the t(8;21). This is the second described case of a de novo AML M2 with t(16;21)(q24;q22) in childhood AML (Jeandidier et al., 2006).

References

Raimondi SC, Kalwinsky DK, Hayashi Y, Behm FG, Mirro J Jr, Williams DL. Cytogenetics of childhood acute nonlymphocytic leukemia. *Cancer Genet Cytogenet* 1989;40(1):13-27.

Berger R, Le Coniat M, Romana SP, Jonveaux P. Secondary acute myeloblastic leukemia with t(16;21)(q24;q22) involving the AML1 gene. *Hematol Cell Ther* 1996;38(2):183-186.

La Starza R, Sambani C, Crescenzi B, Matteucci C, Martelli MF, Mecucci C. AML1/MTG16 fusion gene from a t(16;21)(q24;q22) translocation in treatment-induced leukemia after breast cancer. *Haematologica* 2001;86(2):212-213.

Kondoh K, Nakata Y, Furuta T, Hosoda F, Gamou T, Kurosawa Y, Kinoshita A, Ohki M, Tomita Y, Mori T. A pediatric case of secondary leukemia associated with t(16;21)(q24;q22)

exhibiting the chimeric AML1-MTG16 gene. *Leuk Lymphoma* 2002;43(2):415-420.

Nylund SJ, Ruutu T, Saarinen U, Knuutila S. Metaphase fluorescence in situ hybridization (FISH) in the follow-up of 60 patients with haemopoietic malignancies. *Br J Haematol* 1994;88(4):778-783.

Traweek ST, Slovak ML, Nademanee AP, Brynes RK, Niland JC, Forman SJ. Clonal karyotypic hematopoietic cell abnormalities occurring after autologous bone marrow transplantation for Hodgkin's disease and non-Hodgkin's lymphoma. *Blood* 1994;84(3):957-963.

Shimada M, Ohtsuka E, Shimizu T, Matsumoto T, Matsushita K, Tanimoto F, Kajii T. A recurrent translocation, t(16;21)(q24;q22), associated with acute myelogenous leukemia: identification by fluorescence in situ hybridization. *Cancer Genet Cytogenet* 1997;96(2):102-105.

Takeda K, Shinohara K, Kameda N, Ariyoshi K. A case of therapy-related acute myeloblastic leukemia with t(16;21)(q24;q22) after chemotherapy with DNA-topoisomerase II inhibitors, etoposide and mitoxantrone, and the alkylating agent, cyclophosphamide. *Int J Hematol* 1998;67(2):179-186.

Salomon-Nguyen F, Busson-Le Coniat M, Lafage Pochitaloff M, Mozziconacci J, Berger R, Bernard OA. AML1-MTG16 fusion gene in therapy-related acute leukemia with t(16;21)(q24;q22): two new cases. *Leukemia* 2000;14(9):1704-1705.

Jeandidier E, Dastugue N, Mugneret F, Lafage Pochitaloff M, Mozziconacci MJ, Herens C, Michaux L, Verellen Dumoulin C, Talmant P, Cornillet Lefebvre P, Luquet I, Charrin C, Barin C, Collonge Rame MA, Pérot C, Van den Akker J, Grégoire MJ, Jonveaux P, Baranger L, Eclache Saudreau V, Pagès MP, Cabrol C, Terré C, Berger R. Abnormalities of the long arm of chromosome 21 in 107 patients with hematopoietic disorders: a collaborative retrospective study of the Groupe Français de Cytogénétique Hématologique. *Cancer Genet Cytogenet* 2006;166(1):1-11.

Zatkova A, Fonatsch C, Sperr WR, Valent P. A patient with de novo AML M1 and t(16;21) with karyotype evolution. *Leuk Res* 2007;31(9):1319-1321.

Huret JL. t(8;21)(q22;q22). *Atlas Genet Cytogenet Oncol Haematol* 1997;1(1).

This article should be referenced as such:

Bradtke J, Vorwerk P, Harbott J. A case of trisomy 8 and loss of the Y-chromosome as secondary aberrations in a ten year old boy with de novo AML FAB M2 and t(16;21)(q24;q22). *Atlas Genet Cytogenet Oncol Haematol*.2008;12(6):485-487.
