

Case Report Section

Paper co-edited with the European LeukemiaNet

Translocation t(1;6)(p35;p25) in B-cell lymphoproliferative disorder with evolution to Diffuse Large B-cell Lymphoma

Elvira D Rodrigues Pereira Velloso, Cristina Ratis, Sérgio AB Brasil, João Carlos Guerra, Nydia S Bacal, Cristóvão LP Mangueira

Clinical Laboratory, Hospital Israelita Albert Einstein, São Paulo, Brazil (EDRPV, CAR, NSB, CLPM);
Centro de Hematologia São Paulo, São Paulo, Brazil (SABB, JCG)

Published in Atlas Database: July 2007

Online updated version: <http://AtlasGeneticsOncology.org/Reports/0106RodriguesID100030.html>

DOI: 10.4267/2042/38537

This work is licensed under a Creative Commons Attribution-Non-commercial-No Derivative Works 2.0 France Licence.

© 2008 Atlas of Genetics and Cytogenetics in Oncology and Haematology

Clinics

Age and sex: 75 years old female patient.

Organomegaly:

- hepatomegaly;
- splenomegaly;
- enlarged lymph nodes;
- no central nervous system involvement.

Previous history:

- B-cell Lymphoproliferative disorder for 8 years;
- A 75-years-old female with an 8 years diagnosis of mature B-cell proliferation disorder. At August, 1999 a CBC showed high WBC, and physical examination showed enlarged lymph nodes (cervical and axillaries). Peripheral blood revealed Hb: 14,8g/dl, WBC: 21,8 x 10⁹/l, lymphocytes 16 x 10⁹/l, platelets 241 x 10⁹/l and bone marrow trephine showed interstitial infiltration with small lymphocytes consistent with CLL stage A (Binet). In April, 2000 there was a significant increase in the lymph nodes and night sweats. PB immunophenotyping study showed a CD19/CD5 positive population consisted with B-CLL (Matutes' score 4). The patient was treated with 6 cycles of COP, with evolution to pulmonary nodules and axillae bulky in 2001. From 2001 to 2004, a few cycles of Chlorambucil and 7 cycles of R-COP produced a good response. In April, 2005, the PB morphology and immunophenotype were consistent to atypical B-CLL (CD19, CD20, CD23, CD25, HLA-DR, IgM, IgD, CD79b, CD38, and sKappa, positive and CD5 negative), and PB karyotype showed no clonal abnormalities in 20 metaphases. In August, 2005, there was an increased in the number of lymph nodes and

Rituximab and Fludarabine was started. The PB counts showed: Hb: 13g/dl, WBC: 69,6 x 10⁹/l, lymphocytes: 62 x 10⁹/l, platelets: 145 x 10⁹/l. Inguinal lymph node biopsy showed diffuse large B-cell Lymphoma, Ki-67: 70%, cyclin D1 -, CD20 +, BCL2 +. From December, 2005 to April, 2006, 6 cycles of R-CHOP showed no response. From October, 2006 to May, 2007, regression of lymph nodes and clinical improvement was done with 6 cycles of MiCEP. At this time, cytogenetics and immunophenotyping studies of bone marrow were performed.

Blood

WBC: 5,4 x 10⁹/l; Hb: 13,6 g/dl; platelets: 169 x 10⁹/l; blasts: 3,35 x 10⁹/l (lymphoid cells)%.

Bone marrow: 28% of lymphoid mature cells.

Cytopathology classification

Cytology: B-cell Lymphoproliferative disorder (Atypical CLL) with evolution to diffuse large B-cell Lymphoma. Atypical CLL.

Immunophenotype: 25% of total bone marrow cells are positive : CD20++, CD22+, CD25+, CD38, CD79b++, HLA-DR, sIgM, sIgD e sKappa ++.

Rearranged Ig or Tcr: not done.

Pathology: Inguinal Lymph node biopsy (August, 2005): Diffuse large B-cell Lymphoma, Ki-67: 70%, ciclina D1 -, CD20 +, BCL2 +.

Electron microscopy: not done.

Precise diagnosis: B-cell Lymphoproliferative disorder (Atypical CLL) with evolution to diffuse large B-cell Lymphoma.

Survival

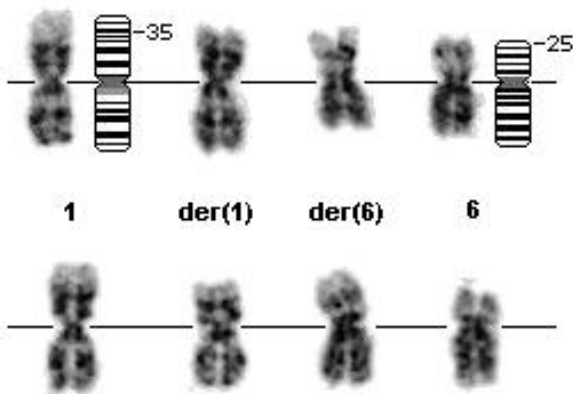
Date of diagnosis: 07-2007.
Treatment: wide previous history (long previous history of chemotherapy), no chemotherapy after July, 2007.
Complete remission: not applied.
Treatment related death: -
Relapse: -
Status: Alive 09-2007.
Survival: 2 months.

Karyotype

Sample: bone marrow cells; culture time: 72 hours with and without TPA (o-tetradecanoyl phorbol-13-acetate); banding: G; results: 47, XX, t(1;6)(p35;p25), +12[13]/46,XX[7].
Karyotype at relapse: not done.
Other molecular cytogenetic techniques: not done.

Other molecular studies

Technics: not done



Partial karyotype, G-band.

Comments

In 2005, the Belgian group described the t(1;6)(p35.3;p25.2) in 8 patients with unmutated B-CLL. As in this case, this rare cytogenetic entity has been described in typical or atypical CLL (8/8 cases), with evolution to diffuse large B-cell Lymphoma (3/8 cases); trisomy 12 been a common additional abnormality (3/8 cases).

References

Michaux L, Wlodarska I, Rack K, Stul M, Criel A, Maerevoet M, Marichal S, Demuynck H, Mineur P, Kargar Samani K, Van Hoof A, Ferrant A, Marynen P, Hagemeijer A. Translocation t(1;6)(p35.3;p25.2): a new recurrent aberration in 'unmutated' B-CLL. *Leukemia* 2005;19:77-82.

This article should be referenced as such:

Rodrigues Pereira Velloso ED, Ratis CA, Brasil SAB, Guerra JC, Bacal NS, Manguera LM Pitanguera CP. Translocation t(1;6)(p35;p25) in B-cell lymphoproliferative disorder with evolution to Diffuse Large B-cell Lymphoma. *Atlas Genet Cytogenet Oncol Haematol.*2008;12(3):258-259.