

Case Report Section

Paper co-edited with the European LeukemiaNet

t(8;13)(p12;q12) in an atypical chronic myeloid leukaemia case

Valeria AS De Melo, Alistair G Reid

Leukaemia Cytogenetics Unit, G Block Room G124, Hammersmith Hospital, Du Cane Road, London W12 0NN, UK

Published in Atlas Database: December 2006

Online updated version: <http://AtlasGeneticsOncology.org/Reports/0813ReidID100018.html>
DOI: 10.4267/2042/38425

This work is licensed under a Creative Commons Attribution-Non-commercial-No Derivative Works 2.0 France Licence.
© 2007 Atlas of Genetics and Cytogenetics in Oncology and Haematology

Clinics

Age and sex: 43 years old male patient.
Organomegaly: no splenomegaly; enlarged lymph node; central nervous system involvement.

Blood

WBC: $9.8 \times 10^9/l$; Hb: 11.5 g/dl; platelets: $28 \times 10^9/l$.

Cytopathology classification

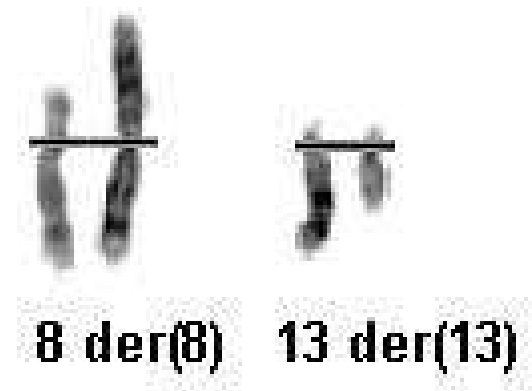
Precise diagnosis: Atypical chronic myeloid leukaemia

Survival

Date of diagnosis: 02-1992.
Treatment: Chemo/Radiation/bone marrow transplantation.
Complete remission was obtained.
Treatment related death: +
Relapse: -
Status: Dead 06-1994
Survival: 28 months

Karyotype

Sample: Bone marrow; Culture time: CM FUDR 48 h;
Banding: G-banding.
Results: 46,XY,t(8;13)(p12;q12)[8]/46,XY[2]



Partial karyotype showing the t(8;13)(p12;q12) - G-banding

Comments

Eight of the metaphases examined showed a translocation between chromosomes 8 and 13. There was no evidence of a Philadelphia translocation. The t(8;13) is usually found in myeloproliferative syndromes with FGFR1 involvement and a poor prognosis

References

Pebusque MJ, Cross NCP. t(8;13)(p12;q12) - updated. Atlas Genet Cytogenet Oncol Haematol 2001;5(1):97-100.

This article should be referenced as such:
De Melo VAS, Reid AG. t(8;13)(p12;q12) in an atypical chronic myeloid leukaemia case. Atlas Genet Cytogenet Oncol Haematol.2007;11(2):151.