

Solid Tumour Section

Mini Review

Thyroid: Anaplastic (undifferentiated) carcinoma

Oluwole Fadare, Giovanni Tallini

Facolta' di Medicina dell' Universita' di Bologna, Sezione Anatomia Patologica, Dipartimento Scienze Oncologiche, Ospedale Bellaria, Via Altura 3, 40139 Bologna, Italy (OF, GT)

Published in Atlas Database: June 2003

Online updated version: <http://AtlasGeneticsOncology.org/Tumors/AnaCarciThyroidID5069.html>

DOI: 10.4267/2042/37995

This work is licensed under a Creative Commons Attribution-Noncommercial-No Derivative Works 2.0 France Licence.
© 2003 Atlas of Genetics and Cytogenetics in Oncology and Haematology

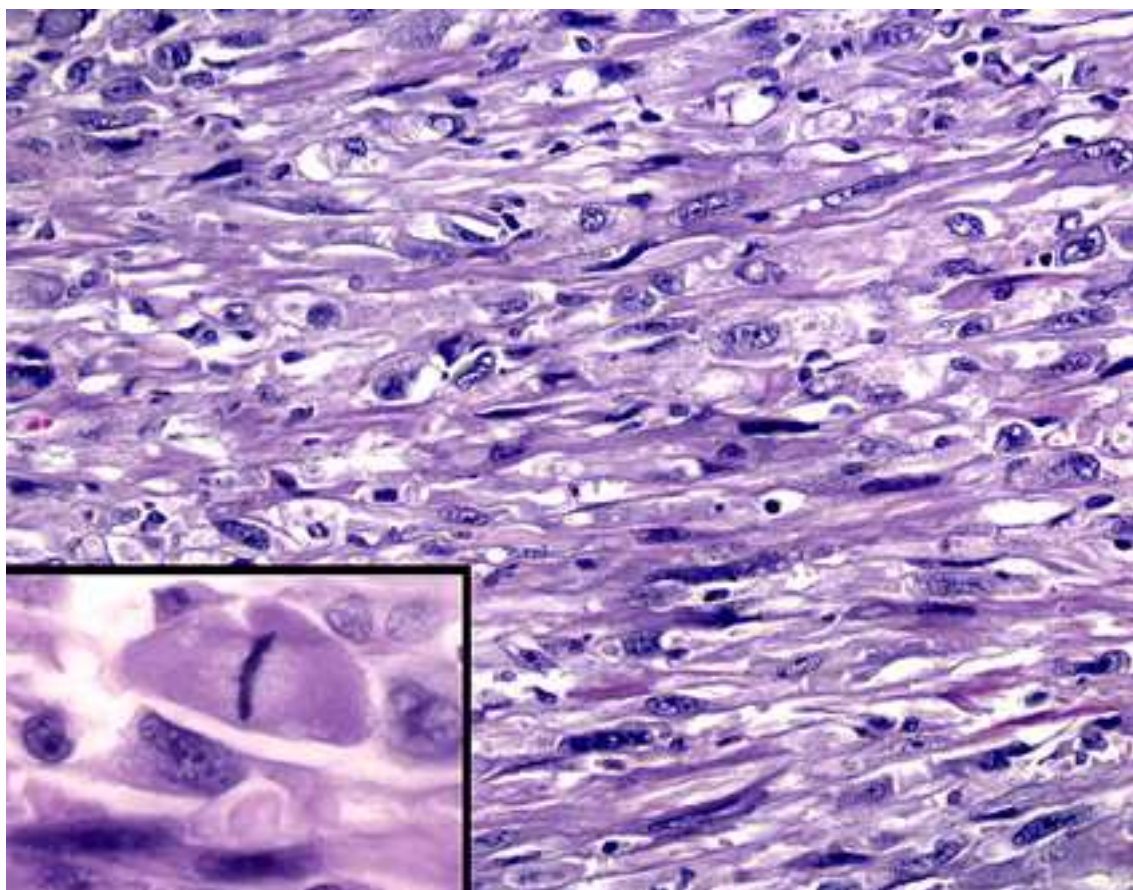
Identity

Note: Anaplastic (undifferentiated) carcinoma of the thyroid gland is a highly malignant tumor composed in part or wholly by undifferentiated malignant cells.

Clinics and pathology

Epidemiology

Anaplastic (undifferentiated) carcinoma of the thyroid gland is uncommon, accounting for less than 5% of all cases of thyroid carcinoma. The average age at diagnosis was 66.5 years, with a female to male ratio of 3.1:1 in one study of 70 cases.



Clinics

Most patients are euthyroid with a history of a rapidly enlarging neck mass. Sometimes, the tumor presents as a new-onset thyroid enlargement in a patient with longstanding thyroid nodule(s) or as the recurrence of a well-differentiated carcinoma. Tumor infiltration of surrounding structures results in secondary symptoms (dyspnea, dysphonia, dysphagia).

Pathology

Tumors are poorly defined, fleshy masses with areas of necrosis and hemorrhage. Microscopically they are composed of anaplastic cells with marked cytologic atypia and high mitotic activity. Tumor necrosis and vascular invasion are common. Histologic patterns include spindle, giant and squamoid cell types. Other patterns (e.g. angiomatoid, carcinosarcoma, lymphoepithelioma-like, adenosquamous) have been described. Undifferentiated (anaplastic) carcinoma of the thyroid must be differentiated from other high grade tumors with similar microscopic appearance originating from adjacent structures in the neck (e.g. larynx). Sometimes this distinction is only possible on clinical/anatomical grounds. Immuno-histochemically, undifferentiated thyroid carcinoma is generally negative for thyroglobulin and calcitonin. Pankeratin and epithelial membrane antigen (EMA) are positive in about one-half and one-third of cases respectively. Thyroid trans-cription factor-1 (TTF-1) staining is present in 0-50% of cases.

Treatment

No effective treatment modalities are currently available.

Prognosis

Anaplastic (undifferentiated) carcinomas are highly aggressive neoplasms that are usually widely invasive at presentation. Regional and distant metastases are common. Most patients die within 1 year of the diagnosis with a median survival of 3.1 months in one study. The 5-year survival rate is around 5%, and the surviving cases are typically small tumors confined to the thyroid amenable to local resection.

Cytogenetics

Morphological cytogenetics

Anaplastic (undifferentiated) carcinoma represents not only morphologically but also in terms of somatic genetic alterations the extreme malignant form of thyroid cancer and as such it is characterized by complex chromosomal alterations.

Molecular cytogenetics

LOH: Allelic loss has been identified at 1q (40%), 9p (58%), 11p (33%), 11q (33%), 17p (44%), 17q (43%), 19p (36%), 22q (38%).

CGH: DNA unbalance can be demonstrated at a variety of chromosomal loci in 80% of undifferentiated carcinomas with a median number of chromosomal losses or gains of 10 per case with abnormal CGH profile. Gains were more common than DNA losses. Loss of chromosomal DNA was identified at 1p, 2q, 4q, 5q, 6q, 8p, 13q, 22q. Specific chromosomal DNA alterations (i.e. 3p13-14+, 5q11-31-, 11q13+) may be associated with the transition from more differentiated phenotypes to anaplastic thyroid cancer.

Genes involved and Proteins

Note: The genetic mechanisms involved with the development of anaplastic thyroid cancer are poorly understood. ATC are characterized by increased cell replication and high Ki67/Mib1 proliferation index, loss of the apoptotic protein bcl-2 and of Fas and its ligand (usually highly expressed in well differentiated thyroid tumors), by an increase in the proapoptotic protein Bax, by Cyclin D1 over-expression and conversely by a fall in the CDK inhibitor p27. It is not clear whether these changes represent the cause or (more likely) the effect of dysregulated cell differentiation and growth in anaplastic cancer.

Mutational inactivation of p53 has been identified in 70-80% of anaplastic carcinomas while H-Ras, K-Ras, or N-Ras activating mutations are present in approximately 50% of the cases. Aberrant Wnt/ beta-Catenin signaling appears to be a distinctive feature of anaplastic thyroid cancer since stabilizing mutations and/or aberrant beta-Catenin nuclear localization are present in 80% of ATC. beta-Catenin nuclear localization is accompanied by its cellular redistribution with marked decrease of the beta-Catenin membrane bound fraction.

References

- Carcangiu ML, Steeper T, Zampi G, Rosai J. Anaplastic thyroid carcinoma: a study of 70 cases. *Am J Clin Pathol* 1985;83:135-158
- Jenkins RB, Hay ID, Herath JF, Schultz CG, Spurbeck JL, Grant CS, Goellner JR, Dewald GW. Frequent occurrence of cytogenetic abnormalities in sporadic nonmedullary thyroid carcinoma. *Cancer* 1990;66:1213-1220
- Rosai J, Carcangiu ML, DeLellis RA. Tumors of the thyroid gland. *Atlas of tumor Pathology*, 3rd series, fascicle 5 1992
- Donghi R, Longoni A, Pilotti S, Michieli P, Della Porta G, Pierotti MA. Gene p53 mutations are restricted to poorly differentiated and undifferentiated carcinomas of the thyroid gland. *J Clin Invest* 1993;91:1753-1760
- Kobayashi T, Asakawa H, Umeshita K, Takeda T, Maruyama H, Matsusuka F, Monden M. Treatment of 37 patients with anaplastic carcinoma of the thyroid. *Head and Neck* 1995;18:36-41.
- Hemmer S, Wasenius VM, Knuutila S, Franssila K, Joensuu H. DNA copy number changes in thyroid carcinoma. *Am J Pathol* 1999;154:1539-1547

Tallini G, Garcia-Rostan G, Herrero A, Zelterman D, Viale G, Bosari S, Carcangiu ML. Downregulation of p27KIP1 and Ki67/Mib1 labelling index support the classification of thyroid carcinoma into prognostically relevant categories. *Am J Surg Pathol* 1999;23:678-685

Kitamura Y, Shimizu K, Tanaka S, Ito K, Emi M. Allelotyping of anaplastic thyroid carcinoma: frequent allelic losses on 1q, 9p, 11, 17, 19p, and 22q. *Genes Chromosomes & Cancer* 2000;27:244-251

Garcia-Rostan G, Camp RL, Herrero A, Carcangiu ML, Rimm DL, Tallini G. Beta catenin dysregulation in thyroid neoplasms: down regulation, aberrant nuclear expression and CTNNB1

exon 3 mutations are markers for aggressive tumor phenotypes and poor prognosis. *Am J Pathol* 2001;158:987-996

Wreesmann VB, Ghossein RA, Patel SG, Harris CP, Schnaser EA, Shaha AR, Tuttle RM, Shah JP, Rao, PH, Singh B. Genome-wide appraisal of thyroid cancer progression. *Am J Pathol* 2002;161:1549-1556

This article should be referenced as such:

Fadare O, Tallini G. Thyroid: Anaplastic (undifferentiated) carcinoma. *Atlas Genet Cytogenet Oncol Haematol.*2003; 7(3):188-190.
